

## Original Research

## A Suture-Button Technique for Stabilization of the Plantar Plate and Lesser Metatarsophalangeal Joint

Molly S. Judge, DPM, FACFAS<sup>1</sup>, Gina Hild, DPM, AACFAS<sup>2</sup><sup>1</sup>Surgeon, Department of Surgery, Mercy Foot & Ankle Residency Program, Cleveland, OH<sup>2</sup>Postgraduate Year 3, Department of Surgery, Mercy Foot & Ankle Residency Program, Cleveland, OH

## ARTICLE INFO

Level of Clinical Evidence: 4

## Keywords:

instability  
joint subluxation  
ligament  
metatarsal  
predislocation syndrome  
toe

## ABSTRACT

We retrospectively evaluated the use of a suture-button technique to stabilize the plantar plate and lesser metatarsophalangeal joint (MTPJ) to alleviate pain and dysfunction due to failed digital surgery with lesser MTPJ dysfunction. Eight consecutive patients (8 feet, 13 rays) were studied, including 2 males (25%) and 6 females (75%). Their median age was 56.5 (range 25 to 72) years, and the median follow-up duration was 28 (range 21 to 36) months. Of the 8 patients, 7 (87.5%) underwent concomitant adjunct procedures. A 10-increment (equal intervals) pain score and the Bristol foot score (BFS) were used to assess subjective satisfaction and foot-related quality of life before and after surgery. The median preoperative pain score was 8 (range 5 to 10). Postoperatively, the median pain score was 0 (range 0), and the difference was statistically significant ( $p = .0106$ ). The median preoperative and postoperative BFS was 53 (range 32 to 70) and 20 (range 18 to 34), respectively. The difference was also statistically significant ( $p = .018$ ). One patient (12.5% of patients, 7.7% of rays) experienced wound dehiscence. All the patients indicated they would undergo the procedure again. From these findings, we believe the described suture-button technique is a useful method to stabilize the plantar plate and MTPJ after failed digital surgery.

© 2017 by the American College of Foot and Ankle Surgeons. All rights reserved.

The inciting factors for chronic and recalcitrant forefoot pain often include, but are not limited to, a long second metatarsal, instability of the second metatarsophalangeal joint (MTPJ), a short first metatarsal, and hypermobility of the first ray. Acute forefoot trauma with resulting plantar plate rupture, subluxation or dislocation of the MTPJ, and a floating toe are also potential causes of forefoot pain (1). Additionally, the complications associated with hallux abductovalgus (HAV) surgery, such as iatrogenic shortening of the first ray with resultant overload of the lesser MTPJs, could warrant surgical correction of the HAV and stabilization of the affected lesser MTPJs.

To address digital instability with metatarsalgia, a number of procedures have been described in published reports. The use of the long flexor tendon transfer was described as early as 1925 (2), with numerous variations reported since then (3–10). By the mid-1980s, Helal and Greiss (11) suggested that the excess length of any given metatarsal could be addressed using telescoping osteotomy. In the same decade, Cracchiolo and Kitaoka (12) described their technique of

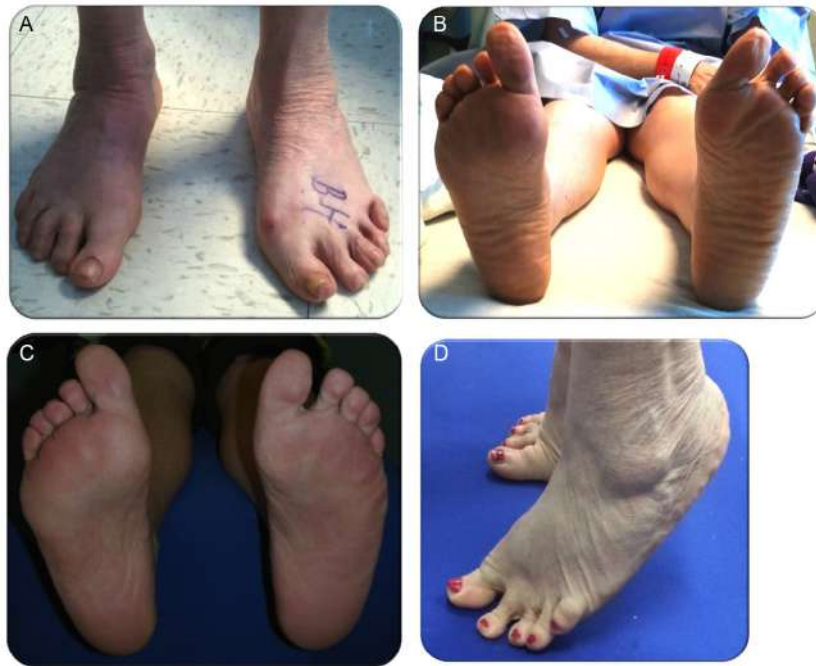inserting a double-stemmed silicone implant into the subluxated lesser MTPJ in an effort to stabilize the joint. Later, Daly and Johnson (13) suggested resection of the involved phalangeal base and partial webbing of the unstable digit to an adjacent, stable toe, as a method to stabilize the subluxated lesser MTPJ. In 1994, Mulier et al (14) described the use of extensor digitorum longus (EDL) transfer to the metatarsal neck (Jones suspension) combined with arthrodesis of the proximal interphalangeal joint (PIPJ) to treat metatarsalgia associated with an unstable MTPJ. Subsequently, Ruch (15) described transfer of the extensor digitorum brevis tendon as a method to stabilize the MTPJ in complex hammertoe repair. Investigators have also described other methods to achieve mulitplanar correction of the subluxated MTPJ since then (16,17).

With the continued interest in dysfunctional digits and lesser metatarsalgia came a focus on the anatomic constraints of the lesser MTPJ. In particular, the nature of the plantar plate and its influence on MTPJ function and stability gained the attention of many foot and ankle surgeons, and the function of the lesser MTPJ plantar plate was likened to that of the first MTPJ sesamoid apparatus. With this focus on the plantar plate, surgical procedures were devised to alter the metatarsal length pattern and stabilize the MTPJ structures to achieve a congruous joint and restore musculotendinous balance by stabilizing the plantar plate (18–25). To the best of our knowledge it was not until 2005 that direct repair of the plantar plate using a plantar incision

**Financial Disclosure:** None reported.**Conflict of Interest:** None reported.

Address correspondence to: Molly S. Judge, DPM, FACFAS, 140 Brookside Drive, Oak Harbor, OH 43449.

E-mail address: [mjudgemolly@aol.com](mailto:mjudgemolly@aol.com) (M. Judge).



**Fig. 1.** (A) Preoperative clinical appearance 10 years after failed reconstructive forefoot surgery that resulted in flail toes 2 to 4 in the left foot. Barefoot activities and simple toe rise maneuvers were intolerable preoperatively. (B) View of fissures separating the compartments of the plantar fat pad of the left foot. During the previous 10 years, this patient had experienced pain and dysfunction owing to the failed forefoot reconstruction. (C) At 8 months after suture-button stabilization of the lesser metatarsophalangeal joints, the plantar fat pad had reorganized and the digits were stable and able to bear weight without pain. (D) At 1 year postoperatively, the patient had returned to her usual daily activities, and the chief complaint of forefoot pain had resolved. At 3 years after the suture-button procedure for digits 2 to 4 of the left foot, she was able to perform the toe rise test without pain, in contrast to the preoperative findings when that maneuver was intolerable.

was advocated by Jolly (26). Jolly promoted the use of small soft tissue anchors to repair the lateral collateral ligament, with release of the medial collateral ligaments, as adjunctive repair in crossover toe deformity. Over time, the combined use of internal fixation, specialized soft tissue anchors and suture materials and purpose-built instrumentation aimed at lesser MTPJ repair became popular. Thus, what seemed to many surgeons to be straightforward lesser MTPJ and plantar plate surgery entered the realm of high technology and relatively expensive specialized instrumentation and implants.

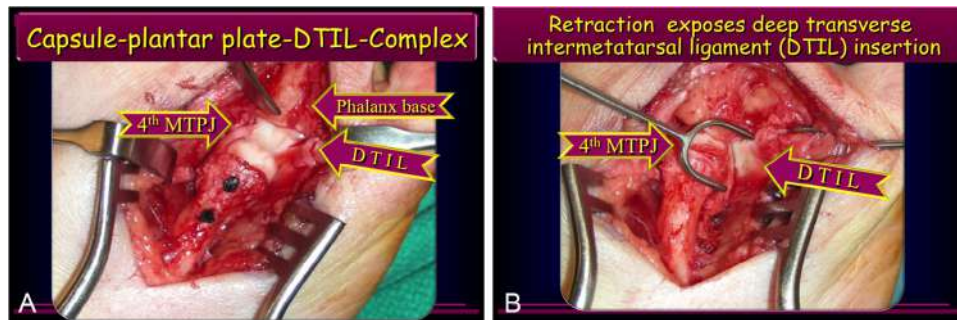
Chronic lesser MTPJ wear and tear and failed lesser toe surgery or trauma can lead to plantar plate attenuation or rupture. Patients with this condition will commonly present with lesser MTPJ instability and toe misalignment in the sagittal, transverse, and frontal planes. In addition, patients can develop degenerative joint disease of the lesser MTPJ, chronic MTPJ, and digital edema, hammer toe, or other interphalangeal contracture. Also, in many cases, a painful plantar keratosis will develop at the level of the metatarsal head, all of these factors contribute to lesser metatarsalgia (Fig. 1). The etiology of plantar plate disruption can be divided into 2 basic groups: patients in whom lesser digital surgery has failed; and patients with MTPJ predislocation syndrome (PDS). In cases of failed digital surgery, it could be that pre-existing plantar plate dysfunction was overlooked, resulting in a poor functional outcome with continued pain. Such patients often report an unsatisfactory outcome after traditional PIPJ fusion or arthroplasty with or without temporary MTPJ transfixation using a Kirschner wire (K-wire).

Just as with many painful musculoskeletal conditions, failure of the condition to satisfactorily respond to nonoperative treatments often results in surgical intervention. In the present report, we have described a series of 8 consecutive patients who experienced chronic

forefoot pain subsequent to lesser MTPJ subluxation and/or failed digital surgery. All 8 patients underwent shortening metatarsal osteotomy, combined with a suture-button technique, to stabilize the involved lesser MTPJs. The aim of the present analysis was to determine whether the suture-button technique, combined with osteotomy, could provide satisfactory pain relief for these conditions and to provide preliminary outcome measures related to this technique. To the best of our knowledge, no previous studies have reported on metatarsal shortening osteotomy combined with the MTPJ suture-button method described in our report.

#### Patients and Methods

In this prospective case series, each patient presented to the senior author (M.S.J.) for consultation regarding chronic intractable forefoot pain due to chronic MTPJ subluxation and/or failed previous digital surgery. On presentation, the patients were considered for inclusion in the present study and informed of the investigation. After the patients had provided informed consent, the pertinent data were collected. Only patients who had presented with chronic forefoot pain associated with subluxation of the MTPJ, recalcitrant to conservative therapy, and after previous digital surgery, were considered for the present review. These patients were identified and enrolled in the series consecutively and were followed up as a group thereafter. To be included, the patients had to experience intractable pain in the forefoot, with swelling and the inability to satisfactorily load bear on the symptomatic MTPJ. In addition, the patients had to display antalgic favoring of the painful foot as a consequence of the intractable pain and swelling. Moreover, to be included, the patients had to have reported that they could not continue their usual daily activities because of their foot pain. Still further, conservative treatment efforts, including the use of metatarsal sling pads and prescription orthotic devices, had to have failed. A total of 11 patients were identified as potentially eligible when they presented; however, 3 patients (27.3%) were excluded because they had had the following exclusion criteria. Of these 3 patients, 1 (33%) had diabetes mellitus and was involved in a litigation claim related to the previous digital surgery, 1 (33%) displayed peripheral neuropathy (33%), and 1 (33%) could not complete the foot-related quality of life questionnaire owing to cognitive impairment.



**Fig. 2.** Dorsal intraoperative view of the lesser metatarsophalangeal joint (MTPJ). (A) The metatarsal was shortened and fixated with 2.0-mm absorbable pins. Distraction exposed the joint capsule, flexor digitorum longus running between the flexor digitorum brevis tendons, deep transverse intermetatarsal ligament (DTIL), and plantar plate. The plantar plate attachment to the base of the proximal phalanx remained intact, with evidence of attenuation. The DTIL can be appreciated as it lies inferior to the lateral retractor and traverses the lateral aspect of the joint. (B) Intraoperative photograph with the metatarsal retracted medially and lateral retraction of the fibrous linkage of the DTIL that runs along the inferior aspect of the MTPJs.

#### Suture-Button Stabilization of the Plantar Plate

The patient was positioned supine with the limb internally rotated for the best exposure. Hemostasis was achieved by anatomic dissection; no tourniquet was used. The target MTPJ was exposed using a dorsal approach. A sequential reduction began proximally at the MTPJ, with longitudinal release of the extensor expansion along the same side as the digital deviation (i.e., when the toe deviated medially, the longitudinal incision was made medial to the EDL tendon). A defect noted within the dorsal distal capsule was considered evidence of herniation of the metatarsal head in cases of severe instability. In the case of PDS, inspection of the joint cartilage failed to reveal an osteochondral defect. Rather, capsular thinning and digital deviation at the MTPJ level were observed. In some cases, the lateral aspect of the metatarsal head was hypertrophic, similar to the eminence seen in a bunion deformity. In digits that had been deformed at the MTPJ for years, release of the plantar plate was performed using an appropriately sized McGlamry metatarsal elevator. A Weil osteotomy (27,28) was then performed in all cases, after which the metatarsal head was retracted to allow visualization of the floor of the joint. The capsule-plantar plate complex looked similar to the superior surface of the sesamoid apparatus present at the first MTPJ. For medially deviated digits, the joint was incised and the metatarsal head retracted laterally to expose the superior surface of the plantar joint capsule, which was visualized superficial to the plantar plate (Fig. 2). Both of these structures, the inferior joint capsule and the plantar plate, were observed to be confluent with the deep transverse intermetatarsal ligament (DTIL) and the flexor tendons. This composite of the lesser MTPJ fibrous capsule, plantar plate, DTIL, and flexor tendons are, in essence, the equivalent of the sesamoid apparatus of the first MTPJ. Typically, this complex will be the same color as tendon, appear smooth with a slight concave depression, and be rubbery in texture. However, when chronic degenerative changes were present, the coloration was yellowish or "tea-stained," with evidence of hemorrhagic infiltrate not unlike that seen in chronic tendinopathy. In cases of lesser MTPJ floor chronic degeneration, attenuation of the plantar structures was present, rather than an overtly torn or ruptured plantar plate. Manipulation of the DTIL further exposed the plantar plate, pulling it from beneath the metatarsal, allowing for closer scrutiny of the complex (Fig. 2). At this point, the size, shape, texture, position, and alignment of the plantar plate were assessed. Definitive fixation of the osteotomy was completed using two 2.0-mm polydioxanone absorbable pins, typically 12 mm each (Fig. 2).

At this point, the tension in the EDL was assessed to determine that it rested under physiologic tension with the MTPJ and PIPJ in neutral position, after which the joint was stabilized using an absorbable suture-button technique. Physiologic tension is that degree of tension that maintains the digit in a corrected position, with the foot, ankle, and MTPJ held in a neutral position. Specifically, a single strand of 3-0 undyed Vicryl® (polyglactin 910; Ethicon, Inc., a division of Johnson & Johnson, Somerville, NJ) was loaded onto 2 Keith needles and, with the foot and ankle held in a neutral position, the MTPJ held in a congruous position, and the corresponding digit held in a neutral to slightly plantarflexed position, depending on the severity of the deformity, the suture was used to stabilize the plantar plate. The suture was run from the capsular tissues at the dorsomedial and dorsolateral aspects of the metatarsal neck inferiorly into the floor of the joint capsule and plantar plate to harness the metatarsal neck in position (Fig. 3). The absorbable suture was positioned such that it would harness the neck of the metatarsal and the base of the phalanx (Fig. 4). The Freer elevator in the upper left corner undermines the capsule-plantar plate-DTIL complex beneath the MTPJ. At the level of the metatarsal neck, passing dorsally to the bones, 4-0 Vicryl® suture (Ethicon, Inc.) was placed distally and 2-0 Vicryl® suture was placed proximally (Fig. 4). The target Keith needle penetration in the region of the plantar plate is shown in Fig. 3D. Hemostats were used to pull the suture through the plantar fat pad, and a similar process was performed for the base of the proximal phalanx, running the suture inferiorly and

proximally to pierce the capsule and plantar plate (Fig. 5). Once the suture was run out of the plantar fat pad of the forefoot, the sutures were attached to a sterile button and secured, holding the joint in a neutral position and with physiologic tension to maintain the digit stable in all 3 cardinal planes (Fig. 5). Because a digit that has been severely contracted for many years can be associated with a soft tissue sleeve and neurovascular structures that could be intolerant to complete reduction of the deformity (as evidenced by excessive skin tension or blanching of the tissues, suggesting vasoconstriction) the surgeon should be cognizant of the soft tissue tension during reduction of the deformity. The suture tension should be decreased in the event of excessive soft tissue tension to prevent neurovascular compromise. Finally, we interposed a drain sponge between the plantar skin and the sterile button to prevent cutaneous compromise. Numerous manual ties were performed to anchor the suture down across the sterile button onto the drain sponge. With the foot at 90° to the leg, the forefoot was placed in the neutral position, and capillary refill to the digital pulp was confirmed before applying the dressing. After administration of a supplemental local anesthetic injection for postoperative anesthesia, a sterile dressing was applied, followed by application of a modified compression dressing.

The postoperative protocol included the use of a modified compression dressing and a cryotherapy unit protected in a heel wedge shoe for 2 weeks. When the incision site had sufficiently coapted, a compressive stocking and heel wedge shoe were continued for a minimum of 6 weeks postoperatively or when the suture-buttons had broken free, typically at 6 to 7 weeks postoperatively. Often, the adjunctive procedures (e.g., metatarsal osteotomy or first MTPJ arthrodesis) dictated when a patient should return to full weightbearing. Once the buttons had been removed, a metatarsal sling pad was used for all weightbearing activities in a firm-soled shoe. Before the patients had undergone surgery, all had been instructed that the use of a metatarsal sling pad would be required for the affected digits as preventative therapy for a lifetime.

#### Outcomes of Interest

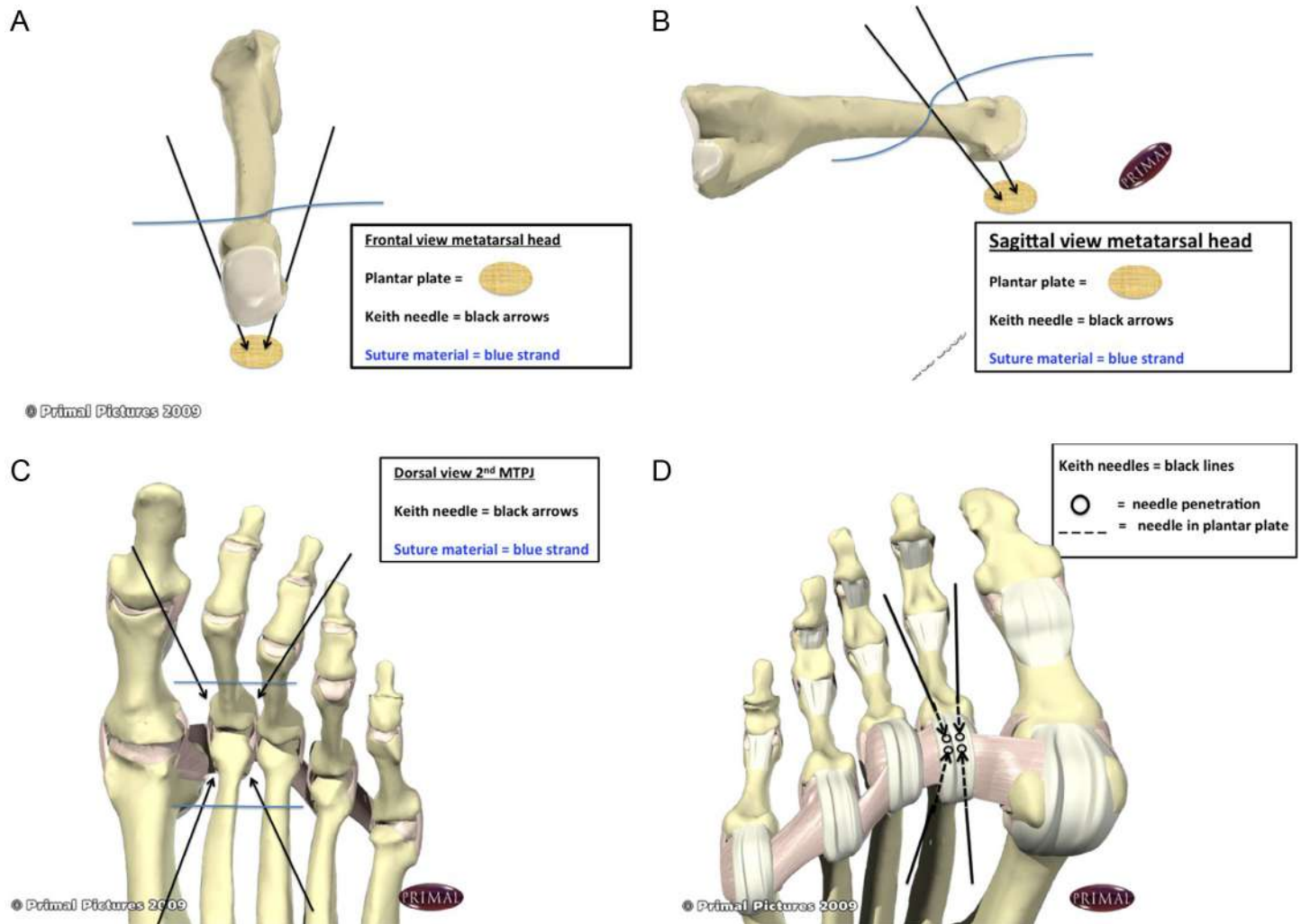
The patients were followed up throughout their postoperative course, monitored for complications, and asked if they would undergo the procedure again to treat the same condition. Moreover, before and after surgery, each patient indicated their pain level using a 10-increment pain scale (29). Also, their foot-related quality of life was assessed using the Bristol Foot Score (BFS) (30). Weightbearing plain radiographs were also taken in the anteroposterior, medial-oblique, lateral, and forefoot axial views of the involved foot. Before the intervention, the patients were advised that the purpose of the surgery was to enhance joint stability in the hope of providing pain relief. As the investigation progressed, the senior author (M.S.J.) abstracted the data from the medical records, performed the surgical intervention, assessed the patients' outcomes, analyzed the data, and collaborated with the coauthor (G.H.) to write the report.

#### Statistical Analysis

Statistically, we considered the data in terms of type and distribution and have described our series of patients in statistical terms. We also used nonparametric null hypothesis tests to compare the preoperative and postoperative outcomes of interest. Furthermore, we stratified the outcomes of interest into groups representative of 30% and 40% improvement. Statistical significance was defined at the 5% ( $p \leq .05$ ) level.

#### Results

The suture-button technique was performed on 13 lesser MTPJs in 8 patients. The surgical procedures were performed between June



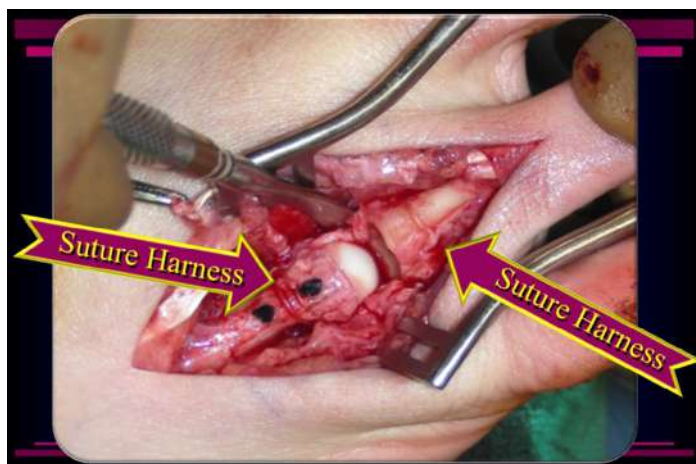
**Fig. 3.** (A) Frontal view diagram of the metatarsal head depicting the suture in Keith needles that are driven down through the plantar plate. This harnesses the metatarsal neck with suture as the needles are driven through the plantar plate and out the plantar fat pad. The suture material is shown in blue, the Keith needles in black, and the plantar plate the color of parchment paper. (B) Sagittal view of the metatarsal depicting the Keith needles maneuvering the suture about the metatarsal neck as they are directed out through the plantar plate. The suture material is shown in blue, the Keith needles in black, and the plantar plate the color of parchment paper. (C) Dorsal view of the second metatarsophalangeal joint (MTPJ), lesser MTPJ regions, and plantar plates linked by the deep transverse intermetatarsal ligaments (DTIL). The Keith needles run down along the lateral aspect of the metatarsal neck and phalangeal base to pierce the plantar plate. (D) Diagram depicting placement of the Keith needles along the base of the proximal phalanx and the metatarsal neck region as they are run out through the plantar plate of the MTPJ. Images reproduced, with permission, from *Interactive Foot & Ankle*. ©Primal Pictures (available at: [www.primalpictures.com](http://www.primalpictures.com)).

2010 and September 2011 (15 months). A statistical description of the series of patients is presented in [Table 1](#) and the outcomes in [Tables 2 and 3](#). The present case series included 8 patients (6 females [75%] and 2 males [25%]). Their median age was 56.5 (range 25 to 72) years. Of these patients, their median body mass index was 27 (range 23 to 31) kg/m<sup>2</sup>, and the median follow-up duration was 28 (range 21 to 36) months.

Of the 8 patients, 5 (62.5%) had a single lesser MTPJ affected, including 4 second MTPJs (50.0%) and 1 fourth MTPJ (12.5%). These 5 patients were all female; 1 (12.5%) had moderate HAV and 1 (12.5%) had severe hallux varus. In 6 digits (46.2%), the lesser MTPJ floor appeared chronically degenerated with attenuation of the plantar structures, rather than appearing overtly torn or ruptured, as viewed at surgical dissection. None of the patients in the present case series displayed frank rupture of the plantar plate. The capsuloligamentous complex of the fourth MTPJ of 1 of the patients is shown in [Fig. 2](#). The floor of the joint was exposed to reveal the capsule, plantar plate, and

DTIL. However, all the patients had significant derangement in the plantar fat pad of the forefoot, ranging from inflammation with diffuse keratosis to very well-localized inflamed bursae and hardened keratoma formations plantar to the affected MTPJs. In each of these cases, moreover, the metatarsal parabola was defective, and decompression using metatarsal osteotomy was deemed necessary.

Of the 8 patients in our series, 6 (75%) reported that they had experienced complications due to failed forefoot surgery performed elsewhere. In 1 male patient (12.5% of 8 patients), lesser MTPJ arthroplasties had resulted in dorsal contractures at MTPJs 2 to 4 and dislocation of the third MTPJ with corresponding semiflexible hammertoe contractures in PIPJs 2 to 4. In another male patient (12.5% of total), failed digital arthroplasties had resulted in increased interdigital splay between the second and third digits associated with severe, semiflexible MTPJ contractures in the right foot ([Fig. 6A](#)). The chronic inflammation from this imbalance was evident in the plantar fat pads beneath MTPJs 2 and 3 ([Fig. 6B](#)). After recovery from surgery,



**Fig. 4.** Intraoperative dorsal view showing the metatarsal neck and phalangeal base have been stabilized using an absorbable suture sling that runs through the plantar plate and out the plantar fat pad of the forefoot. The metatarsophalangeal joint (MTPJ) has been decompressed by metatarsal shortening. With the joint position restored, it is not necessary to violate the articular cartilage with a Kirschner wire and no reason to dissect the proximal interphalangeal joint or distal digit, because the joint decompression has functionally lengthened the long digital tendons and allowed the toe to relax and neutralize distally.

this patient was able to resume his usual weightbearing function, including loading the ball of the foot to raise his heel (Fig. 6C), and the chronic inflammation and keratosis he had experienced had resolved within 4 weeks postoperatively (Fig. 6D). Restoration of flexor digitorum longus (FDL) strength was also observed. The third patient, a female (12.5% of whole group), had experienced chronic pain from failed digital arthroplasties and first metatarsal osteotomy associated with flail toes and severe HAV deformity (Fig. 1). In this patient, the special risks of revisional digital surgery were discussed before the surgery. Before undergoing our procedure, she had had atrophic skin and subcutaneous structures and substantial contractures of soft tissue and tendons, which compounded the complexity of her case. The heightened risk of dysvascularity and wound complications and the potential need for amputation of the digit were all discussed in

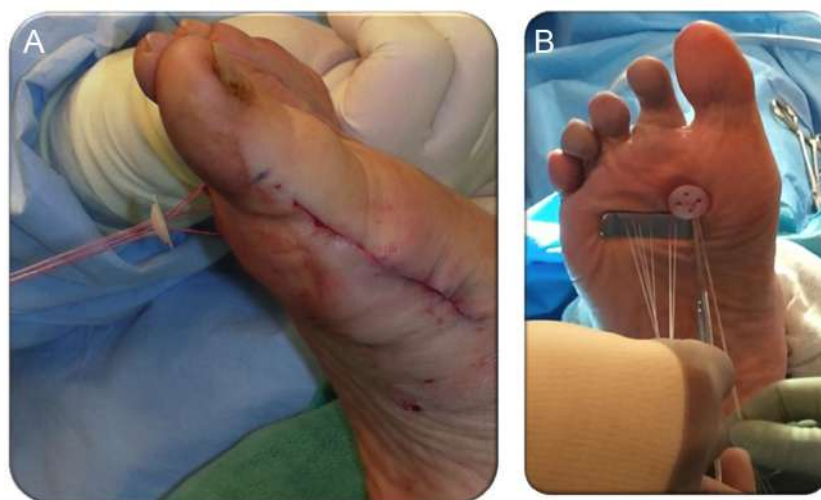**Table 1**

Statistical description of the case series (N = 13 rays in 8 feet in 8 patients)

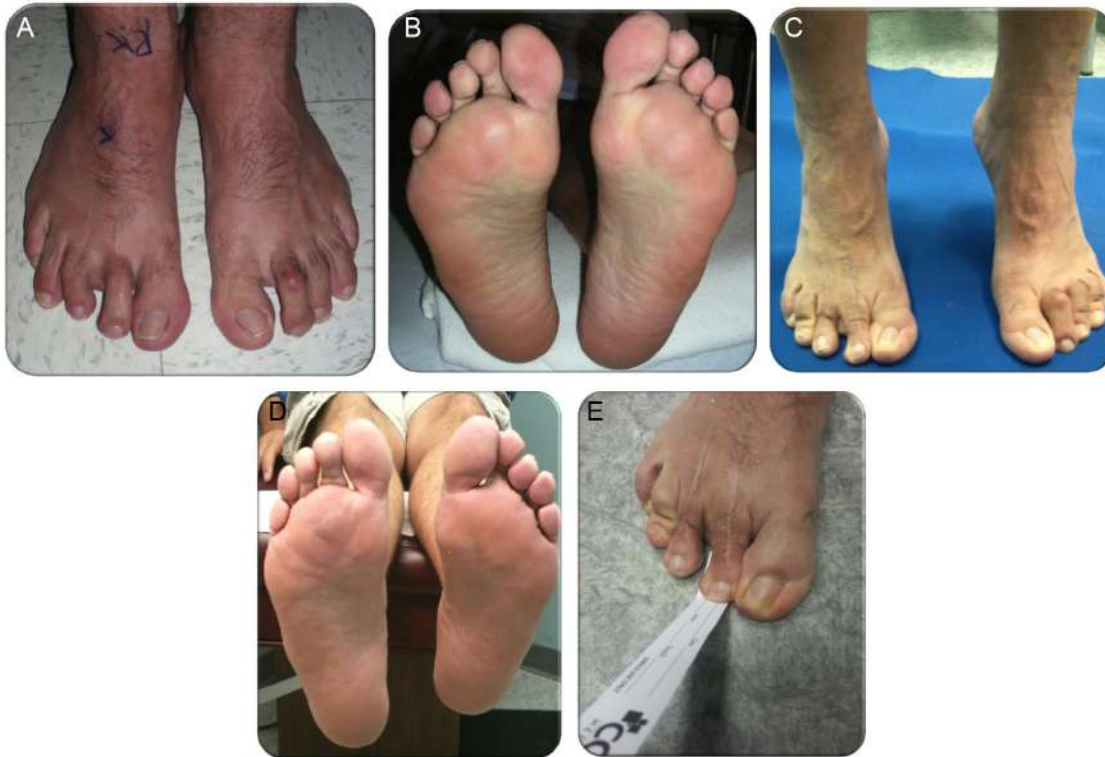Exposure	Median (Range) or n (%)
Age (y)	56.5 (25 to 72)
Age group	
<45 y	2 (25)
≥45 y	6 (75)
Sex	
Female	6 (75)
Male	2 (25)
BMI (kg/m <sup>2</sup> )	27 (23 to 31)
BMI category	
Normal (BMI 18.5 to 24.9 kg/m <sup>2</sup> )	2 (25)
Overweight (BMI 25 to 29.9 kg/m <sup>2</sup> )	3 (37.5)
Obese (BMI ≥30 kg/m <sup>2</sup> )	3 (37.5)
Anatomic side	
Right	5 (62.50)
Left	3 (37.50)
Bilateral	0
Ray involved	
Isolated lesser central	5 (62.5)
Multiple lesser central	3 (37.5)
Isolated second ray	4 (50)
Isolated fourth ray	1 (12.5)
Adjunct surgery	
None	1 (12.5)
Same ray, PIPJ fusion	4 (50)
Ipsilateral first ray	3 (37.5)
Follow-up (mo)	28 (21 to 36)

Abbreviations: BMI, body mass index; PIPJ, proximal interphalangeal joint.

detail with the patient. In another female patient (12.5%), an attempt at soft tissue correction for hallux varus associated with second toe contracture failed to reduce the pain or deformity. A third female patient (12.5%) had experienced trauma to the second digit and, despite open reduction and internal fixation and continued to have swelling, pain, PIPJ malunion, and stiffness. The fourth female patient (12.5%) experienced continued subsecond MTPJ pain despite first metatarsal osteotomy and second toe arthroplasty. Finally, 2 of the 8 patients (25%) had developed MTPJ deformity and dysfunction without having undergone previous surgery. Of the latter 2 patients, 1 (12.5% of total group) had developed posttraumatic pain and instability owing to an untreated digital fracture. In the second patient (12.5%), the MTPJ



**Fig. 5.** (A) Photograph showing suture run out the plantar fat pad to secure the right second metatarsophalangeal joint (MTPJ). The suture was run out the plantar fat pad with the MTPJ position neutral in 3 cardinal planes. (B) The suture was fed through a sterile button and tensioned down until the button rested against the plantar skin. A series of manual ties secured the button to a drain sponge to prevent skin irritation.



**Fig. 6.** Failed right forefoot surgery. (A) The patient presented with recalcitrant chronic pain with weightbearing and an inability to tolerate barefoot activity. Note the digital contractures with multiplanar deformities despite attempted surgical correction 5 years previously. (B) The plantar fat pad was deranged, with enlarged bursal projections that were well-delineated and appeared to be inflamed in the right submetatarsal 2 and 3 region, with diffuse hyperkeratosis. (C) Toe rise maneuver was possible >2 years after the suture-button technique had been performed. (D) Note that the plantar fat pad had reorganized as the bursal projections were resorbed, with resolution of the fat pad inflammation at 2.5 years postoperatively. (E) Photograph >2 years after the suture-button technique showing the patient able to perform positive grip strength. Although our technique cannot be expected to restore long tendon function when a digit has been dysfunctional for many years, for patients with intact long tendon function preoperatively, that function will be maintained with successful completion of this technique.

deformity and dysfunction had resulted from recalcitrant PDS secondary to flexor instability. All the patients reported that they could not tolerate walking barefoot, with significant disruption of their activities of daily living preoperatively.

Six types of adjunctive procedures were performed with the suture-button technique. These included 13 lesser metatarsal osteotomies (8 second [61.5%], 3 third [23.1%], and 2 fourth [15.4%]), 1 first metatarsal osteotomy (12.5%), 2 first MTPJ arthrodeses (25%), 4 PIPJ arthrodeses (31.1%), 3 second digit interphalangeal exostectomies (23.1%), 1 third digit interphalangeal exostectomy (7.7% of rays), 1 hallux interphalangeal exostectomy (7.7% of rays), and 1 Akin osteotomy (12.5% of patients).

Using the incremental pain scale (Table 2), the median preoperative score was 8 (range 5 to 10), and the final postoperative score was 0. This difference was statistically significant ( $p = .0106$ ). All 8 patients (100%) experienced at least a 40% decrease in pain (Table 3). Using the BFS (Table 2), the median preoperative score was 53 (range

32 to 70). The final BFS score was 20 (range of 18 to 34). This difference was also statistically significant ( $p = .018$ ). Of the 8 patients, 7 (87.5%) experienced  $\geq 30\%$  improvement in their BFS, and 6 (75%) experienced  $\geq 40\%$  improvement in their BFS (Table 3). Furthermore, 1 patient (12.5% of patients; 7.7% of rays) experienced wound dehiscence, which healed with local wound care. Also, all the patients indicated they would undergo the procedure again for the same condition.

## Discussion

The present report serves as an extension of the work by Gerard V. Yu, DPM (deceased) in addressing the chronic and debilitating pain syndrome that can accompany lesser MTPJ instability most accurately described as PDS (31,32). In PDS, weakness and instability result in imbalance of the MTPJ. When the second MTPJ is involved, the principle structures that become weakened include the second dorsal

**Table 2**

Comparison of preoperative and postoperative pain and foot-related quality of life (N = 13 rays in 8 feet in 8 patients)

Measure	Preoperatively	Postoperatively	p Value*
10-Increment pain score	8 (5 to 10)	0 (0)	.0106
Bristol Foot Score†	53 (32 to 70)	20 (18 to 34)	.018

Data presented as mean (range).

\* Wilcoxon signed ranks test.

† Score range from a minimum of 15 (best) to a maximum of 73 (worst).

**Table 3**

Outcomes stratified by percentage of improvement (N = 13 rays in 8 feet in 8 patients)

Outcome	30% Improvement	40% Improvement
10-Increment pain score	8 (100)	8 (100)
Bristol Foot Score*	7 (87.5)	6 (75)

Data presented as n (%).

\* Score range from a minimum of 15 (best) to a maximum of 73 (worst).

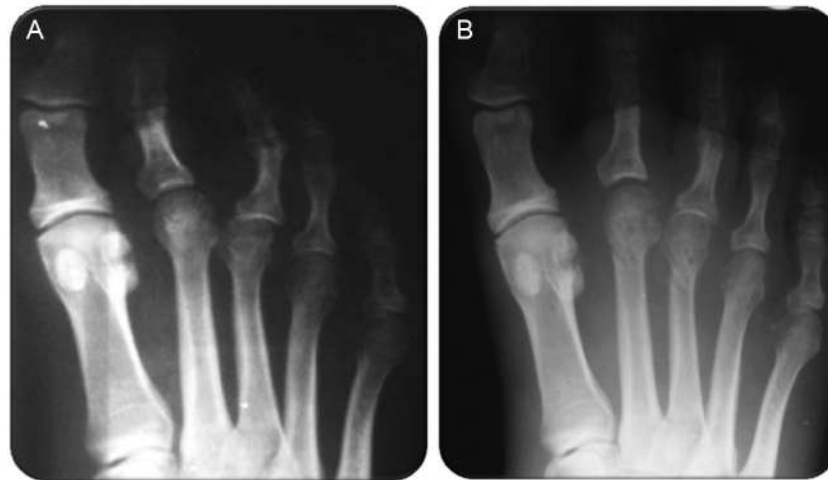interosseous muscle, FDL, plantar plate, and first lumbrical, resulting in sagittal and transverse plane instability of the MTPJ. Specifically, weakness in each of these structures in the second ray contributes to slow, progressive elevation at the MTPJ (weakened first lumbrical), medial subluxation of the toe (weakness of the second dorsal interosseous), mild and reducible flexion contracture at the PIPJ, and plantar pain beneath the base of the digit (weakness of the FDL and chronic inflammation of the plantar plate). In our experience, conservative therapy can often provide sufficient comfort and adequate return to function, thereby obviating the need for surgery for many patients. However, for the subset of patients in whom conservative therapy fails, chronic forefoot pain due to plantar plate insufficiency, edema, degenerative joint disease of the lesser MTPJ, and painful plantar keratosis formation are among the conditions that lead to severe disability and intractable pain at the base of a digit and within the ball of the foot. Metatarsalgia due to PDS and complications from failed digital surgery accounted for the disability and chronic forefoot pain in the patients described in the present case series. In these patients, the physical disability and emotional upheaval from the chronic pain had become unbearable. In some patients, the disability interfered with gainful employment, reduced their ability to cope with daily activities, interfered with their sleep–wake cycle, and was mood altering, affecting their entire family. In our experience, the condition of these patients is often misdiagnosed as a neuroma or simple hammertoe deformity, and other patients are misconstrued as malingerers. When lesser MTPJ dysfunction has been misdiagnosed, surgery can fail to stabilize the MTPJ, resulting in recalcitrant or worsened pain.

In more traditional hammertoe surgery, when release of the plantar MTPJ is required, K-wire stabilization (transfixation) of the joint has been commonly used. Although such pinning has been shown to stabilize the joint and prevent recurrence of deformity in the short term (33), no long-term radiographic or clinical analyses have ever been reported, to the best of our knowledge. To effectively stabilize the MTPJ, a K-wire can be retrograded across the joint and seated in the cancellous bone of the metatarsal base to prevent premature loosening and extrusion of the pin. This retrograde pinning of the digit is tedious and can require >1 attempt to achieve neutral joint alignment. Using a 0.062-in. K-wire to transfixate the joint often results in more than one 1.6-mm hole in the subchondral bone plate and joint cartilage (34). Given that the metatarsal head contact area is small, repeated attempts at pinning across the joint could damage the articular surfaces. Although the clinical significance of this has yet to be determined, we suspect that repeated punctures through the cartilage could invoke degenerate changes, and prolonged K-wire fixation of the lesser MTPJ could result in persistent joint stiffness, which could complicate recovery and reduce long-term satisfaction. It is important to understand that instability of the MTPJ–plantar plate complex can exist independently of hammertoe contracture. Also, these deformities can be separate and distinct clinical entities (e.g., PDS). The potential complications of digital arthroplasty and arthrodesis can often be avoided once the MTPJ–plantar plate complex has been stabilized. Because arthroplasty and arthrodesis of the digit includes dissection of the digital soft tissues, lymphatic and other small caliber neurovascular structures will be manipulated and can potentially be injured, resulting in chronic edema that can be very difficult, if not impossible, to reduce in some patients. Alternatively, decompression of the MTPJ, whether from simple release of the MTPJ or shortening of the metatarsal segment, will result in relaxation or functional lengthening of the long tendons, with subsequent reduction of flexible digital contractures. This virtual lengthening of the tendons could obviate the need for digital arthroplasty or arthrodesis. The suture-button technique we have described could then be used as an adjunct procedure to secure the plantar plate and stabilize the floor of the joint to secure the plantar plate to the underlying joint capsule while the tissues heal over time.

When the length pattern of the ray is the primary deformity, metatarsal osteotomy can often be beneficial (18–21,23,24). A variation on that theme is en bloc bone resection from the metatarsal neck and shaft, stabilized with a 1/4-in. tubular plate and screws (21). Alternatively, others have proposed that direct repair of the plantar plate is necessary to restore balance and function about the digit (18). In 1 technique described by Weil et al (24), the plantar plate was sutured with a stitch run through a bone tunnel within the proximal phalanx to stabilize the plate relative to the bone. Weil et al (24) documented good results for numerous patients, although their technique required tunneling of the small cortical margins of the proximal phalanx and completely detached the plantar plate before its repair. We believe the suture-button technique we have described has distinct advantages in that it does not detach the plantar plate and it uses absorbable suture to secure the complex. Moreover, bone tunnels are not needed; therefore, the technique avoids the complications that could accompany bone work (understanding that a Weil osteotomy was used with the suture-button). Another advantage of the suture-button technique is that it can avoid the need to open the digital sleeve and deglove the digit altogether, because most of the incision spans the metatarsal neck and terminates at the base of the proximal phalanx. Hence, in many cases, it will not be necessary to violate the bone at the digital base or interphalangeal joint. Collectively, these advantages reduce the complexity of the procedure, reduce the risk of bone complications in the digit, and eliminate violation of the digital sleeve and articular surfaces, which can result in longstanding edema, neuritis, and stiffness.

The suture-button technique we have described is essentially a culmination of the ideas explored by others during the past 8 decades. Our technique can be most likened to the Lambrinuidi external digital splint described in the report by Taylor (4), in which suture was used to anchor the proximal phalanx, with the suture run out the sole of the foot and postoperative shoe. Cicchinelli (35) has also thoroughly discussed the concept of addressing digital pathology at the level of the MTPJ as the primary procedure to reverse digital contracture. Also, it was a personal communication with Cicchinelli that led to the development of our described technique. The concept of harnessing the proximal phalanx base and anchoring it in position can be traced back in published reports to as early as 1925 (10) and has been the focus of subsequent procedures geared at stabilizing the second digit. The earliest reported procedure described an FDL tendon transfer to the proximal phalanx (2). However, the concept of plantar plate stabilization or repair was not considered at that time. In the present case series, the Girdlestone method (36) of harnessing the proximal phalanx was simulated and taken a step further by also harnessing the metatarsal neck to stabilize both the phalanx base and the metatarsal head to the plantar plate and underlying soft tissue bed. The procedure we have espoused anchors the plantar plate in place using absorbable suture strands that course out of the foot through the plantar fat pad of the forefoot. No special equipment is needed for this procedure; thus, the technique is relatively inexpensive in terms of the materials needed to complete the maneuver. The procedure requires only Keith needles, a sterile button, and absorbable suture. Just as with all surgical interventions, the mere cost of the materials used in the operation is only 1 facet of cost-effectiveness, and a thorough cost-effectiveness analysis, complete with a definition of quality-adjusted life-years, is required to define the cost-effectiveness of this technique compared with any other.

The suture-button technique we have described also proved effective in complicated cases with failure of previous forefoot surgery. It was important to have the patients demonstrate their ability (or inability) to rise up on their toes (heel raise) and to actively hold their toes against the ground in the preoperative examination, allowing for a clear understanding of their baseline function. The goal, especially



**Fig. 7.** (A) Preoperative weightbearing dorsoplantar radiographs displaying deformity at the second and third metatarsophalangeal joints (MTPJs), with medial subluxation of the second MTPJ and dorsal dislocation at the third MTPJ present for 5 years after previous digital surgery. (B) Weightbearing films 6 weeks after the suture-button procedure with 2nd and 3rd metatarsal ostotomies revealing improved position of the lesser MTPJs.

in the cases of failed digital surgery, was pain relief, with was no guarantees regarding a change in toe function or cosmesis. We believe this approach was prudent, because some of the toes had not been able to grip the ground for years. Using the suture-button procedure, combined with the Weil osteotomy, the long tendon function to the toe was maintained if normal grip strength was evident before surgery. Using the “paper pull out test,” the patient shown in Fig. 6E was able to grip a piece of paper and resists its pull out postoperatively. Also, in the same patient, plain radiographs had revealed interdigital splay and third MTPJ dislocation before surgery (Fig. 7A); however, the postoperative radiographs showed improved joint congruity after stabilization using our technique (Fig. 7B).

In all cases in our series, Weil osteotomy was performed as described previously (19,27,37,38). Also, we stabilized the osteotomy using dual absorbable pins. The osteotomy functionally changes the axis of motion, similar to that noted with decompression osteotomy for hallux limitus.

Inspection of the MTPJ joint cartilage was always performed. However, in the cases of PDS, no gross osteochondral defect was ever identified. Similar to the findings in hallux abductovalgus deformity, the articular cartilage of the lesser metatarsal was typically intact and healthy appearing. The exception in our series included 3 patients (37.5%) whose joints were complicated by previous arthrodesis or arthroplasty. In the 8 digits (61.5%) of these 3 patients, cartilage derangement and hypertrophic degenerative changes of the metatarsal head were evident years after the index procedures of PIPJ arthrodesis and MTPJ pinning. In 1 patient (12.5%), >8 years of semirigid and rigid joint contractures had resulted in these degenerative changes of the lesser MTPJs. In such cases, we believe that release of the plantar plate is required owing to the presence of longstanding adhesion formation. In the present case series, ≤3 years of radiographic follow-up confirmed bone and joint stability. Moreover, in our experience to date, we have not had to perform direct open repair of the plantar plate.

Regarding revision of PIPJ arthrodesis, we performed this in 4 toes (30.1%). In each case, we did not transfixate the MTPJ with a K-wire. By using absorbable suture, the inflammatory reaction about the joint was relatively short lived, and, because absorbable suture is not stiff, it will not physically irritate the adjacent tissues, in contrast to non-absorbable materials. One case of wound dehiscence (12.5%) developed

in a patient who, incidentally, was an active tobacco user; however, our analyses did not enable us to elucidate the precise association of any exposure to this complication.

The exclusion criteria in the present study were used to eliminate variables that could interfere with evaluation of the patients and their subjective input. Joint dysfunction due to hyperglycemia and generalized glycosylation of tissues throughout the forefoot, joint derangement due to neuropathic joint injury, legal issues, or a patient's inability to participate in the preoperative and postoperative interviews were considered major variables that could likely skew the data. Therefore, the patients with diabetes, peripheral neuropathy of any etiology, an active worker's compensation case, and cognitive disability were not included.

Using the suture-button technique we have described has been very rewarding to date, both for us as surgeons and for our patients. This suture-button technique for stabilization of the lesser MTPJ is distinctive in that it does not disrupt the flexor tendons or the plantar plate, in contrast to direct open repair. It uses absorbable suture to anchor the bone against the plantar plate, resulting in stabilization of the entire MTPJ complex. In essence, we believe this provides physiologic restoration of joint congruity and positioning of the joint over the plantar plate, which, in turn, enables the long tendons to regain their mechanical advantage across the MTPJs. This functional lengthening of the tendons often allows avoidance of osseous procedures commonly performed at the PIPJ level, although metatarsal osteotomy seems to be necessary to address misalignment of the metatarsus. A further benefit of this method, compared with K-wire transfixation is that an external K-wire is not maintained at the tip of the digit during the early postoperative phase, a known subjective preference of patients. Still further, our suture-button procedure is technically simple and likely to be cost-effective.

One important weakness of our study was that a single surgeon performed the clinical and radiographic evaluations and all the operations, which could have imparted the biases inherent whenever surgeons analyze their own work. Another weakness was the small size of the case series. We recognize that well-designed cohort studies and randomized controlled trials are required to validate our clinical outcomes. Nonetheless, we believe that the present findings can be used in the development of more rigorous and less-biased clinical investigations. Since the time this article was submitted, 6 of the 8



patients in this study remain in the senior author's practice. Each would have their procedure preformed again if necessary.

In conclusion, we believe that the success of the presented suture-button technique, performed in conjunction with metatarsal osteotomy, results from the enhanced stability of the complex structure composed of the plantar plate, ligaments, and joint capsule of the MTPJ. In the present group of patients, the technique was used to successfully stabilize the lesser MTPJ, eliminate pain, improve function, and impart substantial subjective patient satisfaction.

## Acknowledgments

In memory of Dr. Gerard V. Yu, whose zest for life and insatiable intrigue for details have made a true difference for foot and ankle surgeons worldwide. A deep debt of gratitude to Dr. Scot Malay for his expertise in statistical analysis and depth of knowledge for the pathology studied herein. Special thanks also for the efforts of the medical library staff at the Health Science Library, Mercy St. Vincent Medical Center of Toledo, Ohio, for their assistance in research and acquisition of studies required for our report.

## References

- Baravarian B, Thompson J, Nazarian D. Plantar plate tears: a review of the modified flexor tendon transfer repair for stabilization. *Clin Podiatr Med Surg* 28:57–68, 2011.
- Trethowan WH. The treatment of hammertoe. *Lancet* 1:1312, 1925.
- Forrester-Brown MF. Tendon transplantation for clawing of the great toe. *J Bone Joint Surg* 20:57, 1938.
- Taylor RG. The treatment of claw toes by multiple transfers of flexor into extensor tendons. *J Bone Joint Surg Br* 33-B:539–542, 1951.
- Pyper JB. The flexor-extensor transplant operation for claw toes. *J Bone Joint Surg Br* 40-B:528–533, 1958.
- McCain L. Transplantation of the flexor digitorum brevis in hammer toe surgery. *J Am Podiatry Assoc* 48:233–235, 1958.
- Sgarlato TE. Transplantation of the flexor digitorum longus muscle tendon in hammertoes. *J Am Podiatry Assoc* 60:383–388, 1970.
- Marcinko DE, Lazerson A, Dollard MD, Schwartz N. Flexor digitorum longus tendon transfer: a simplified technique. *J Am Podiatry Assoc* 74:380–385, 1984.
- Kuwada GT. A retrospective analysis of modification of the flexor tendon transfer for correction of hammer toe. *J Foot Surg* 27:57–59, 1988.
- Losa Iglesias ME, Becerro de Bengoa Vallejo R, Jules KT, Trepal MJ. Meta-analysis of flexor tendon transfer for the correction of lesser toe deformities. *J Am Podiatr Med Assoc* 102:359–368, 2012.
- Helal B, Greiss M. Telescoping osteotomy for pressure metatarsalgia. *J Bone Joint Surg Br* 66:213–217, 1984.
- Cracchiolo A III, Kitaoka HB, Leventen EO. Silicone implant arthroplasty for second metatarsophalangeal joint disorders with and without hallux valgus deformities. *Foot Ankle* 9:10–18, 1988.
- Daly PJ, Johnson KA. Treatment of painful subluxation or dislocation at the second and third metatarsophalangeal joints by partial proximal phalanx excision and subtotal webbing. *Clin Orthop Relat Res* 278:164–170, 1992.
- Mulier T, Dereymaeker G, Fabry G. Jones transfer to the lesser rays in metatarsalgia: technique and long-term follow-up. *Foot Ankle Int* 15:523–530, 1994.
- Ruch J. Use of the EDB tendon for muscle-tendon balance of the lesser MPJ. In: *Update '95. Reconstructive Surgery of the Foot and Leg*, pp. 114–118, edited by CA Camasta, NS Vickers, SE Carter, Podiatry Publishing Company, Tucker, GA, 1995.
- Hobizal KB, Wukich DK, Manway J. Extensor digitorum brevis transfer technique to correct multiplanar deformity of the lesser digits. *Foot Ankle Spec* 9:252–257, 2016.
- Blazek CD, Brandão RA, Manway JM, Burns PR. Multiplanar correction of the lesser digital deviation and indirect plantar plate rupture repair using a braided polyethylene nylon suture: a technique guide. *Foot Ankle Spec* 2017 Aug 1. doi:10.1177/1938640017724544. [Epub ahead of print].
- Blitz NM, Ford LA, Christensen JC. Plantar plate repair of the second metatarsophalangeal joint: technique and tips. *J Foot Ankle Surg* 43:266–270, 2004.
- Goforth WP, Overbeek TD, Odom RD, Roe TG, McDonald DK. Lesser-metatarsal medial displacement osteotomy for the treatment of digital transverse plane deformities. *J Am Podiatr Med Assoc* 95:550–555, 2005.
- Myerson MS, Jung HG. The role of toe flexor-to-extensor transfer in correcting metatarsophalangeal joint instability of the second toe. *Foot Ankle Int* 26:675–679, 2005.
- Galluch DB, Bohay DR, Anderson JG. Midshaft metatarsal segmental osteotomy with open reduction and internal fixation. *Foot Ankle Int* 28:169–174, 2007.
- Bouche RT, Heit EJ. Combined plantar plate and hammertoe repair with flexor digitorum longus tendon transfer for chronic, severe sagittal plane instability of the lesser metatarsophalangeal joints: preliminary observations. *J Foot Ankle Surg* 47:125–137, 2008.
- Salari N, Faro FD, Miller SD. Dorsal opening wedge osteotomy of second proximal phalanx for second MTP dorsiflexion. *Foot Ankle Int* 31:1021–1024, 2010.
- Weil L Jr, Sung W, Weil LS Sr, Malinoski K. Anatomic plantar plate repair using the Weil metatarsal osteotomy approach. *Foot Ankle Spec* 4:145–150, 2011.
- Highlander P, VonHerbulis E, Gonzalez A, Britt J, Buchman J. Complications of the Weil osteotomy. *Foot Ankle Spec* 4:165–170, 2011.
- Jolly G. Second metatarsophalangeal joint instability. In: *The Foot and Ankle*, ed. 1, Lippincott Williams & Wilkins, Philadelphia, 2005.
- Barouk LS. [Weil's metatarsal osteotomy in the treatment of metatarsalgia]. *Orthopade* 25:338–344, 1996.
- Canale ST, Beatty JH. Congenital clubfoot (talipes equinovarus). In: *Campbell's Operative Orthopaedics*, ed. 11, Elsevier, Philadelphia, 2007.
- Wessel J. The reliability and validity of pain threshold measurements in osteoarthritis of the knee. *Scand J Rheumatol* 24:238–242, 1995.
- Barnett S, Campbell R, Harvey I. The Bristol Foot Score: developing a patient-based foot-health measure. *J Am Podiatr Med Assoc* 95:264–272, 2005.
- Yu GV, Judge MS, Hudson JR, Seidelmann FE. Predislocation syndrome: progressive subluxation/dislocation of the lesser metatarsophalangeal joint. *J Am Podiatr Med Assoc* 92:182–199, 2002.
- Yu GV, Judge MA. Predislocation syndrome of the lesser metatarsophalangeal joint, a distinct clinical entity. In: *Reconstructive Surgery of the Foot and Leg*, edited by CVN Camasta, SR Carter, Podiatry Publishing Company, Tucker, GA, 1995.
- Downey M, McGlamry MC, Spizzirri SA. Transverse plane digital deformities. In: *McGlamry's Comprehensive Textbook of Foot and Ankle Surgery*, ed. 4, p. 222, edited by JT Southerland, Lippincott Williams & Wilkins, Philadelphia, 2013.
- Galli MM, Brigido SA, Protzman NM. Pinning across the metatarsophalangeal joint for hammertoe correction: where are we aiming and what is the damage to the metatarsal articular surface? *J Foot Ankle Surg* 53:405–410, 2014.
- Cicchinelli L. Second metatarsophalangeal joint instability: the tree in the forest. In: *Update 2011*, pp. 139–147, Podiatry Institute, Decatur, GA, 2011.
- Girdlestone GR. Physiotherapy for hand and foot. *J Chartered Soc Physiother* 32:167, 1947.
- Trnka HJ, Gebhard C, Muhlbauer M, Ivancic G, Ritschl P. The Weil osteotomy for treatment of dislocated lesser metatarsophalangeal joints: good outcome in 21 patients with 42 osteotomies. *Acta Orthop Scand* 73:190–194, 2002.
- Trnka HJ, Muhlbauer M, Zettl R, Myerson MS, Ritschl P. Comparison of the results of the Weil and Helal osteotomies for the treatment of metatarsalgia secondary to dislocation of the lesser metatarsophalangeal joints. *Foot Ankle Int* 20:72–79, 1999.