

EFFICACY OF SUBTALAR JOINT ARTHRODESIS FOR CORRECTION OF PÆS VALGO PLANUS DEFORMITY: A Retrospective Evaluation

Gerard V. Yu, D.P.M.

Molly S. Judge, D.P.M.

Many surgical procedures have been described and advocated for the surgical correction of the adult acquired flatfoot deformity, definitively referred to as collapsing pes valgo planus deformity. While triple arthrodesis has been the time-honored procedure for correction of severe deformity, with or without concomitant degenerative arthritis in the adult patient, there has been a significant interest in the use of isolated joint arthrodesis (subtalar, talonavicular or calcaneocuboid) and even joint preservation procedures (calcaneal osteotomy, subtalar joint arthroereisis, medial column osteotomy) usually employed only in the juvenile or adolescent patient. The senior author has utilized isolated subtalar joint arthrodesis in lieu of triple arthrodesis in patients with a significant symptomatic flatfoot deformity unresponsive to conservative treatment modalities with excellent success.

A retrospective radiographic review was undertaken to assess the efficacy of this procedure to correct significant peritalar subluxation as evidenced on conventional weight-bearing pedal radiographs. Common radiographic parameters were measured on preoperative and postoperative radiographs and a statistical analysis of the results performed. Our results indicate that an isolated subtalar joint arthrodesis can be a very powerful procedure resulting in multiplanar correction of a severe flatfoot deformity.

HISTORICAL REVIEW

Isolated subtalar joint arthrodesis has been used to correct foot deformities secondary to injury or paralysis since 1907. In 1916, Willard reported on the use of this procedure in lateral deformities of paralytic feet. It was not until 1943, however, that the orthopedic literature reflected the use of isolated subtalar joint arthrodesis for correction of the pronated foot in the nonparalytic patient. Credit

is given to Leavitt, who performed subtalar joint arthrodesis with satisfactory results in 8 patients.

In 1945, Grice advocated an extra-articular approach to arthrodesis of the subtalar joint in juvenile patients with a paralytic valgus foot deformity. This extra-articular block prevented posterior and lateral rotation of the calcaneus, and thus the rest of the foot, stabilizing the rearfoot and preventing malalignment between the talus and calcaneus. By 1960, Grice extended the indications for his operation to encompass a complex array of diagnosis including vertical talus deformity, talocalcaneal coalitions, idiopathic pes plano valgus, as well as valgus deformities secondary to cerebral palsy and myelodysplasia. After reporting on more than 100 cases, his confidence in the procedure's effectiveness grew, and he felt the procedure could abolish the need for triple arthrodesis in young children.

Other authors have also published reports on the effectiveness of the Grice procedure, but with a somewhat less than optimal outcome in all patients. Ross and Lyne performed a retrospective evaluation of 113 patients, including 28 patients with "relaxed flat feet," and indicated poor results were typically due to malposition of the graft attributed to technical error in its placement at the time of fusion. The results were unsatisfactory in patients with valgus deformities that were the result of neuromuscular conditions, myelodysplasia and flexible flatfeet, and they felt the procedure was of limited value.

Current interest in isolated subtalar joint arthrodesis to correct multiplanar flatfoot deformity is high, especially with the increased awareness and recognition of the adult acquired flatfoot deformity secondary to tibialis posterior tendon dysfunction or rupture. Only advocates of isolated midtarsal joint arthrodesis rival interest and study of this joint, whether it is the talonavicular or

calcaneocuboid joint. Unfortunately, while several articles have studied the implications of isolated rearfoot arthrodesis in cadaver specimens, few studies have reported on the efficacy of such an approach in actual patients. The authors have not been able to identify any publications which have assessed the efficacy of an isolated joint fusion to correct single or multiplanar deformity based on the peritalar relationships seen on weight-bearing radiographs before and after the fusion procedure.

Major rearfoot fusions have been criticized for many years as posing undue stress across other joints of the midfoot and ankle. There is a false presumption that stress is translated into degenerative changes within the affected adjacent joints, purportedly "taking up the stress." Recent literature, however, has shown quite the contrary and should rightfully dispel these commonly accepted "myths."

Mann and Baumgarten reviewed 11 patients who underwent an isolated subtalar joint arthrodesis an average of 41.5 months postoperatively. With an average of six degrees of valgus alignment to the hindfoot, only minimal changes were noted radiographically within the midtarsal complex. In addition, these radiographic changes were not clinically significant.

In 1988, Russotti et al. reviewed 45 isolated subtalar joint arthrodesis procedures with an average follow-up of 57 months, and found no associated secondary degenerative changes in the adjacent hindfoot joints. More recently, de Heus conducted a large follow-up study of subtalar joint and triple arthrodesis procedures, and offered several favorable comments regarding outcomes via the Mazur scoring system. Little adverse influence on the function of the tibiotalar joint was identified in either group of patients, even after many years.

INDICATIONS

Isolated subtalar joint arthrodesis may be indicated in patients with a symptomatic acquired or congenital flatfoot deformity, which may be single, or multiplanar in nature. The more common etiologies are tibialis posterior tendon dysfunction or rupture, tarsal coalition, and benign hypermobile joint syndrome. While flexibility is very desirable and helpful in achieving proper relocation of the foot to a neutral attitude when performing this procedure, a semi-rigid deformity or "tracking"

subtalar joint can also be corrected with an isolated subtalar joint fusion providing there is relatively normal architecture to the tarsal bones and rearfoot and midfoot joints. Its absence may suggest the need for additional intra- or extra-articular procedures to ensure proper alignment of the forefoot on the rearfoot, once the subtalar joint has been returned to a more neutral attitude.

The primary clinical indications are pain and disability secondary to a collapsing pes valgo planus deformity with or without rearfoot instability, which is unresponsive to conservative treatment modalities such as custom orthotic devices, supportive shoes, or ankle and leg braces. The ability to perform normal activities of daily living are usually compromised to varying degrees. It is not uncommon for patients to have abandoned their normal walking or similar exercise programs due to chronic symptomatology. Postural symptoms such as lower back pain, fatigue and knee or hip pains are common complaints.

Normal, limited or excessive motion may be present with or without crepitus upon active or passive range of motion manipulation. Difficulty with ambulating and weight bearing for even short periods of time are not uncommon. Some patients will report significant difficulty with climbing stairs, ladders, or the manipulation of machinery with foot pedals.

Conventional weight-bearing radiographs usually reveal significant peritalar subluxation as evidenced by such parameters as decreased talonavicular congruity, decreased height of the navicular from the ground supporting surface, as well as abnormalities of angular determinations such as the talocalcaneal angle, talar declination angle, and calcaneocuboid angle. While significant joint malposition is present and expected, normal osseous architecture should be present. Significant degenerative changes may be present within the subtalar joint itself, but should be absent from the midtarsal and midfoot articulations. The presence of significant secondary changes, (i.e. significant subchondral sclerosis or juxta-articular exostosis formation), like significant architectural changes of the tarsal bones, implies the need for double or more commonly triple joint arthrodesis.

In addition to weight-bearing radiographs, dorsoplantar and lateral x-rays should be obtained with the foot in a "neutral position" or the "desired position of fusion" to confirm the ability to restore proper alignment and position to the foot. The

inability to restore the foot to the desired position of fusion preoperatively may predict failure of an isolated subtalar joint arthrodesis.

MATERIALS AND METHODS

A retrospective study of 44 patients (48 feet) was compiled with the assistance of the podiatric residency-training program of PHS-Mt. Sinai Medical Center-University Circle and the private practice of the senior author in Cleveland, Ohio. All patients in the study were initially examined and diagnosed by the senior author. The medical charts and preoperative and postoperative x-rays of all patients were reviewed to generate results and formulate conclusions. All radiographic measurements were determined by the same investigators to ensure consistency and minimize error. The senior author reviewed the methods and results for each patient.

All patients included in the study had a symptomatic collapsing pes valgo planus deformity as the primary reason for undergoing an isolated subtalar joint arthrodesis. Any patient who had an isolated subtalar joint arthrodesis for another primary diagnosis (bone tumor, post-traumatic arthritis as a result of malunion of a calcaneal fracture) or insufficient preoperative or postoperative radiographs were excluded. A solid clinical and radiographic arthrodesis had to be identified with a minimum of 1 month of ambulatory status. The presence of a bone healing complication also excluded the patient from being included in the study.

The patient population studied consisted of 26 females and 18 males. The age range of patients was from 14 to 78 years, with an average of 41.56 years. The follow-up ranged from 3 months to 45 months with an average of 13.08 months. All patients had a primary diagnosis of symptomatic collapsing pes valgo planus deformity or adult acquired flatfoot syndrome, which was the primary indication for undergoing the isolated subtalar joint arthrodesis. Additional diagnoses assigned to patients by the senior author included tibialis posterior tendon dysfunction/rupture (23 patients), tarsal coalition (8 patients), peroneal spastic flatfoot (4 patients), ankle equinus (8 patients), painful os tibiale externum (6 patients), subtalar joint degenerative arthritis/joint disease (6 patients), ankle joint synovitis (2 patients), and subtalar joint

instability (4 patients). Other diagnoses of the forefoot that may or may not have required surgery were not recorded.

All patients underwent subtalar joint arthrodesis with internal fixation using a 6.5-mm or 7.0-mm long thread cancellous screw, or a 7.3-mm cannulated cancellous screw for primary fixation of the posterior facet of the subtalar joint. In addition to the primary fixation screw, 24 of the 48 procedures included a secondary point of fixation. These included the use of a secondary Kirschner wire or Steinmann pin (6 patients), a second large cancellous screw (11 patients), one or two 4.0-mm cancellous bone screws to fixate a bone graft within the sinus tarsi area (2 patients) or a combination of an additional small cancellous screw(s) and Kirschner wire(s) (2 patients).

Ancillary procedures were performed in 32 of the 48 cases and included a tibialis posterior tendon repair (4 patients), tarsal coalition resection (6 patients), peroneus brevis tendon lengthening (5 patients), gastrocnemius recession or tendoAchilles lengthening (10 patients), modified Kidner procedure (6 patients), ankle arthroplasty (9 patients), and ankle synovectomy (1 patient). One patient underwent simultaneous correction of multiple digital deformities.

Preoperative and postoperative weight-bearing dorsoplantar and lateral radiographs were reviewed. The radiographic parameter studied on the dorsoplantar films included the talocalcaneal angle (TCA), talonavicular congruity (TNC) and calcaneocuboid angle (CCA). The radiographic parameters studied on the lateral films included the talar declination angle (TDA), talo-first metatarsal angle (T-1stMA), and navicular height (NH) and calcaneal inclination angle (CIA). Measurements were taken from both the preoperative and longest-term follow-up radiographs and the differences between the two calculated and recorded.

RESULTS

Results from the dorsoplantar radiographs were as follows. The preoperative TCA ranged from 4 to 60 degrees with an average of 23.88 degrees. The postoperative TCA ranged from 8 to 22 degrees with an average of 12.13 degrees. The average change in the TCA was a decrease of 11.54 degrees with a range of (-6) to 52 degrees. The pre-

operative CCA ranged from 8 to 42 degrees with an average of 22.15 degrees. The postoperative CCA ranged from (-6) to 36 degrees with an average of 11.65 degrees. The average change in the CCA was a decrease of 10.50 degrees with a range of (-35) to 10 degrees. The TNC congruity preoperatively ranged from 40% to 100% with an average of 64.69%. The TNC congruity postoperatively ranged from 50% to 110%, with an average of 90.94% congruity. The average change in TNC was an increase of 26.25% with a range of change from 0 to 45% (Table 1).

Results from the lateral radiographs were as follows. The preoperative TDA ranged from 12 to 55 degrees with an average of 31.90 degrees. The postoperative TDA ranged from 3 to 30 degrees with an average of 18.33 degrees. The overall change was a decrease in TDA of 13.35 degrees with a range of 4 to (-42) degrees. The preoperative T-1stMA ranged from 0 to 43 degrees with an average of 20.52 degrees. The postoperative T-1stMA ranged from (-8) to 15 degrees with an average of 4.04 degrees. The overall change was a decrease of 16.48 degrees with a range of change from 8 to (-43) degrees. The preoperative TCA ranged from 30 to 75 degrees with an average of 48.13 degrees. The postoperative TCA ranged from 0 to 53 degrees with an average of 35.77 degrees. The average change was a decrease in the TCA of 12.40 degrees with a range of change from 3 to (-34) degrees. The preoperative CIA ranged from 0 to 28 degrees with an average of 15.71 degrees. The postoperative CIA ranged from 8 to 32 degrees with an average of 18.06 degrees. The overall change in the CIA was an increase of 2.73 degrees with a range of change

Dorsal-Plantar Radiograph

DORSAL-PLANTAR RADIOGRAPH	PREOP	POSTOP	CHANGE
TCA AVERAGE	23.88	12.13	(-11.54)
TCA RANGE	4 to 60	8 to 22	(-6) to 52
TNC AVERAGE	64.69%	90.94%	26.25%
TNC RANGE	40 to 100%	50 to 110%	0 to 45%
CCA AVERAGE	22.15	11.65	(-10.50)
CCA RANGE	8 to 42	(-6) to 36	(-35) to 10

Table 1

from (-3) to 14 degrees. The preoperative NH ranged from 3 to 45 mm with an average of 20.65 mm. The postoperative NH ranged from 16 to 46 mm with an average of 30.40 mm. The overall change in NH was an increase of 9.75 mm with a range of (-7) to 20 mm (Table 2).

DISCUSSION

Triple arthrodesis is the time-honored procedure for the correction of a severe collapsing pes valgo planus deformity in the adult patient. This is particularly true when symptoms have been unresponsive and recalcitrant to conservative treatment modalities. The effectiveness of this procedure to alleviate symptoms and to provide structural correction is well known to the orthopedic and podiatric communities. In certain patients, it continues to be the procedure of choice, especially when significant tarsal and mid-tarsal arthritis exists with or without significant osseous adaptation. It may also be indicated in patients with an underlying neuromuscular disorder where proper muscle tendon balance cannot predictably be restored.

In many situations, the joints and tarsal bones may be spared significant changes. In those patients, it should be considered unfortunate and undesirable to perform a procedure which destroys three major intertarsal joints (triple arthrodesis) of the rearfoot complex. It is always easier to accept the fate of a triple arthrodesis when degenerative arthritis accompanies significant malalignment as evidenced by subluxation or luxation of the subtalar and/or midtarsal joints.

Lateral Radiograph

LATERAL RADIOGRAPH	PREOP	POSTOP	CHANGE
TCA AVERAGE	48.13	35.77	(-12.40)
TCA RANGE	30 to 75	0 to 53	3 - (-34)
T-1st MA AVERAGE	20.52	4.04	(-16.48)
T-1st MA RANGE	0 to 43	(-8) to 15	8 to (-43)
TDA AVERAGE	31.09	18.33	(-13.35)
TDA RANGE	12 to 55	3 to 30	4 to (-42)
NH AVERAGE	20.65	30.40	9.75
NH RANGE	3 to 45	16 to 46	(-7) to 20
CIA AVERAGE	15.71	18.06	2.73
CIA RANGE	0 to 28	8 to 32	(-3) to 14

Table 2

While much of the earlier orthopedic literature has suggested that isolated subtalar joint arthrodesis is likely to result in degenerative changes of the midtarsal and/or ankle joint(s), more current articles suggest otherwise. The senior author's 13 years of experience in private practice confirms the more recent literature. The authors strongly believe that the benefits of an isolated subtalar joint arthrodesis over a triple arthrodesis are very much worthwhile.

The findings of the authors strongly support the concept of multiplanar correction of a flatfoot deformity by isolated subtalar joint arthrodesis in lieu of triple arthrodesis. Significant changes in the talar declination angle, talocalcaneal angle, talo-1st metatarsal angle, calcaneocuboid angle, talonavicular congruity and navicular height can be expected. Changes in the calcaneal inclination angle are not likely to be significant. The radiographic changes that were observed strongly suggest that peritalar subluxation can be corrected by means of an isolated joint arthrodesis.

While much of the literature has recommended that rearfoot and ankle fusion be accomplished with slight valgus, the authors recommend a neutral position fusion of the subtalar joint, or in cases where deformity exists above the level of the malleoli a position which will result in the heel being perpendicular to the ground supporting surface. It is felt that the closer the position of fusion to neutral, the less likely the patient is to develop degenerative arthritic changes of the more proximal or more distal joints. Likewise, failure to achieve a more neutral position of fusion is likely to be associated with greater clinical symptomatology with degenerative changes noted on pedal radiographs. The ultimate goal should be to align the rearfoot with a vertical attitude to the ground-supporting surface, with minimal, if any frontal plane valgus or eversion. The presence or absence of frontal plane deformation of the tibial segment will influence the relationship of the calcaneus to the long axis of the tibia when performing subtalar arthrodesis. For example, in patients with significant tibial varum, the calcaneus may be fused to the talus in slight valgus with respect to the tibia, yet result in a vertically oriented heel with weight bearing.

The position of fusion will determine the success of the procedure. Thus, emphasis should be placed on proper positioning of the calcaneus with respect to the talus when performing isolated

subtalar joint arthrodesis. The authors routinely employ the curettage technique for resection of the joint surfaces, thereby preserving the normal architecture and contour of the facets. This in turn facilitates proper positioning. Loss of height and widening of the foot are minimized with this technique. Neutral position of the subtalar joint is achieved by careful manipulation and palpation of the talonavicular and subtalar joints in addition to direct observation of the talocalcaneal relationship through the lateral incision.

Once the proper position has been identified, efforts should be made to maintain the position by use of a Kirschner wire or Steinmann pin placed at a location other than the anticipated site of the primary compression screw. The authors frequently insert a pin or wire into the calcaneus at the anterior leading edge of the talus. This pin or wire is oriented perpendicular to the posterior articular facet and parallel to the anterior surface of the lateral process of the talus. It does not violate the talus at any point, but rather serves as an "arthroereisis" type of device preventing malposition during the course of the fusion procedure. Temporary or permanent placement of this device commits to memory the position of fusion. At the same time, it allows the surgeon to distract, visualize, resect and reposition the subtalar joint during the course of surgery as often as needed prior to final fixation. The technique referred to as a "Sta-Pin" has been described in previous literature by the senior author.

Successful use of an isolated subtalar joint arthrodesis for correction of peritalar subluxation requires adequate flexibility of the deformity. While this can be readily assessed clinically, the authors recommend that the dorsoplantar and lateral radiographs be obtained with the foot in "neutral" position or the "desired position of fusion." These x-rays should confirm the clinical impressions and findings, and provide a reference point during surgery to ensure the proper position of fusion is in fact achieved (Figs. 1A-1F, 2A-2E). Intra-operative images can be compared to the preoperative radiographs to confirm that the desired position of fusion has been obtained prior to the insertion of permanent fixation. The more flexible the deformity the easier it will be to manipulate the foot into the corrected position. The more rigid the foot, the more difficult it is to achieve the desired position.

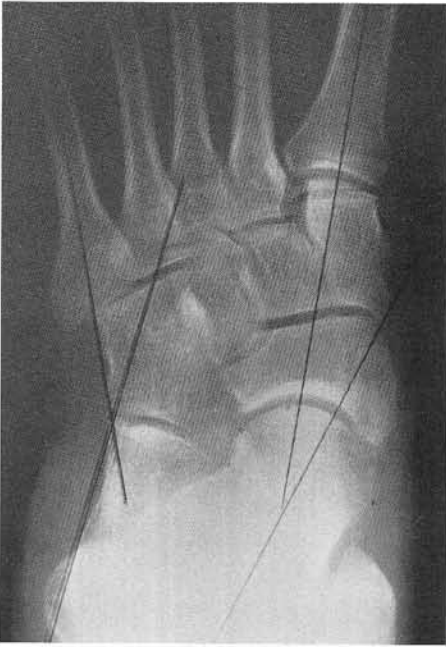

Figure 1A. Dorsoplantar weight-bearing radiograph of a patient with an adult acquired flatfoot syndrome secondary to long-standing tibialis posterior tendon dysfunction. Note the degree of peritalar subluxation indicative of pronation. The lines shown are used to determine radiographic parameters.

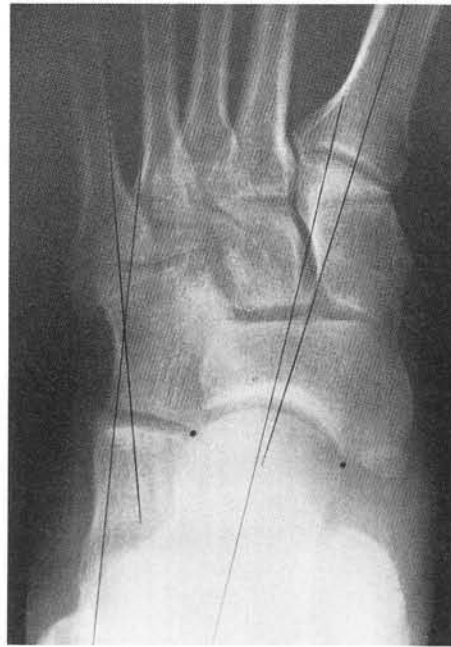

Figure 1B. Dorsoplantar neutral position radiograph. Total restoration of alignment has been achieved. This is the desired position of fusion for this patient.

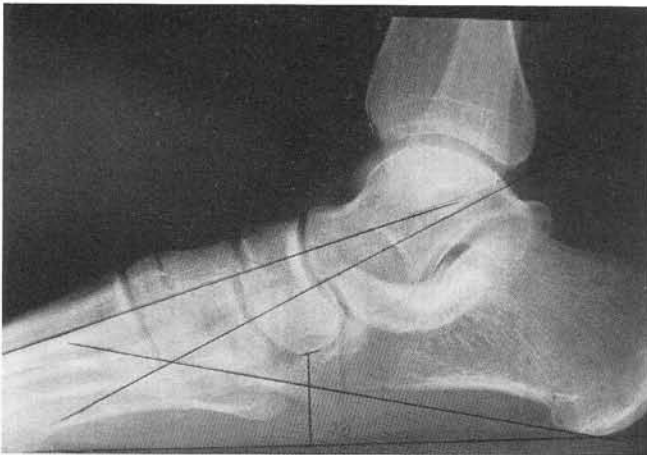

Figure 1C. Lateral weight-bearing radiograph. Some early secondary changes are noted in the tarsal joints evidenced by increased sclerosis and some very early beaking at the medial column articulations. The deformity was considered semiflexible.

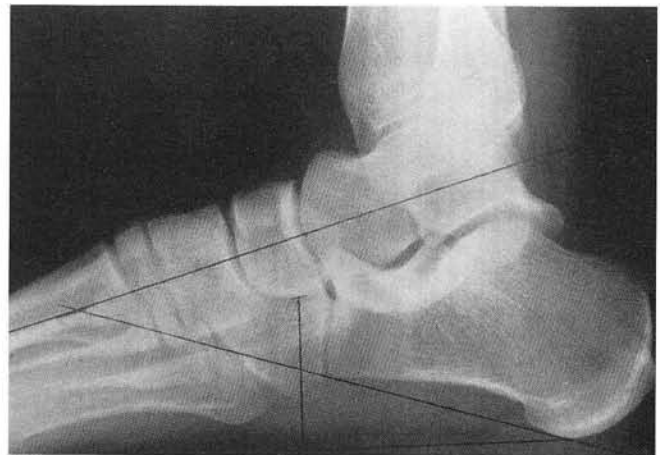

Figure 1D. Lateral neutral position radiograph. Total restoration of alignment has been achieved. This is the desired position of fusion for this patient.

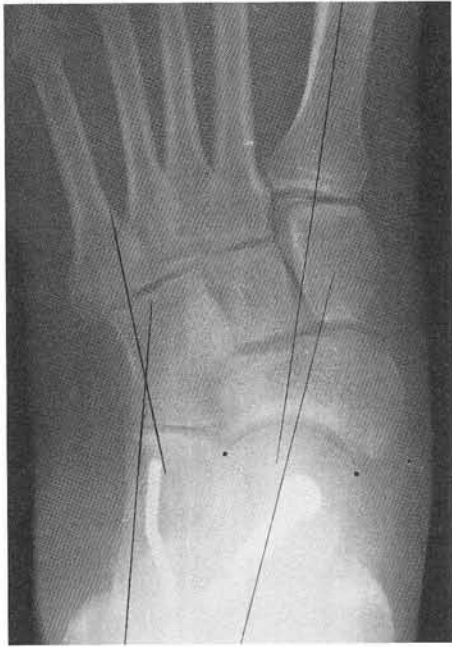

Figure 1E. Long-term follow-up weight-bearing radiograph. The patient is now 2 years postoperative and has had an excellent clinical outcome and result.

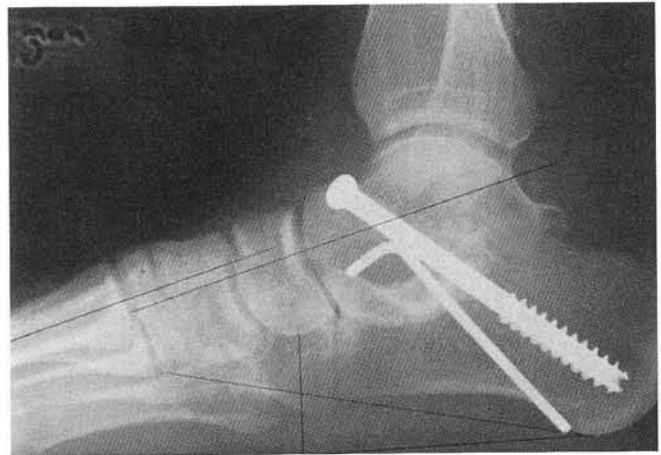

Figure 1F. Lateral view, long-term follow-up weight-bearing radiograph.

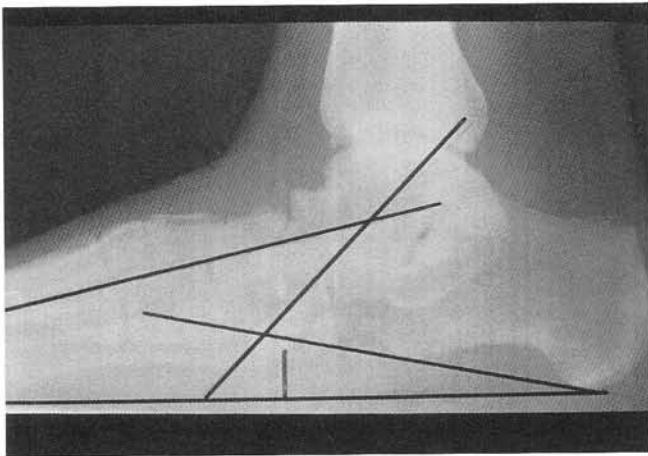


Figure 2A. Lateral weight bearing radiograph of a patient with adult acquired flatfoot syndrome secondary to longstanding tibialis posterior tendon dysfunction. Note the adaptive and secondary changes at the talar neck area.

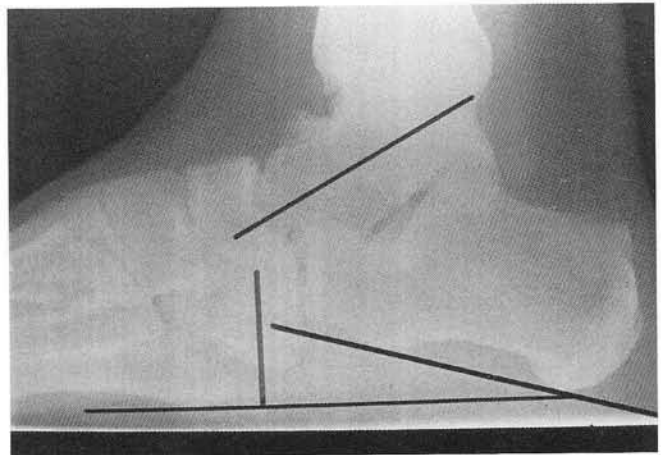


Figure 2B. Neutral position lateral radiograph. Note the significant improvement in the subtalar and midtarsal joint alignment. This was the desired position of fusion for this patient.

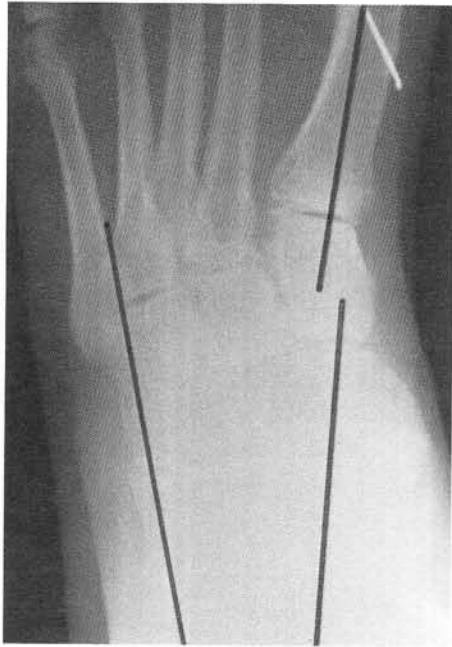

Figure 2C. Long-term follow-up radiograph taken in a weight-bearing relaxed position 13 months postoperatively. Note the excellent alignment of the subtalar and midtarsal joint complexes. The patient had previous correction of a hallux abductus valgus deformity prior to the rearfoot fusion. Although not appreciated on this radiograph, the patient had significant forefoot varus not reduced at the time of surgery. An ankle arthroplasty was also performed.

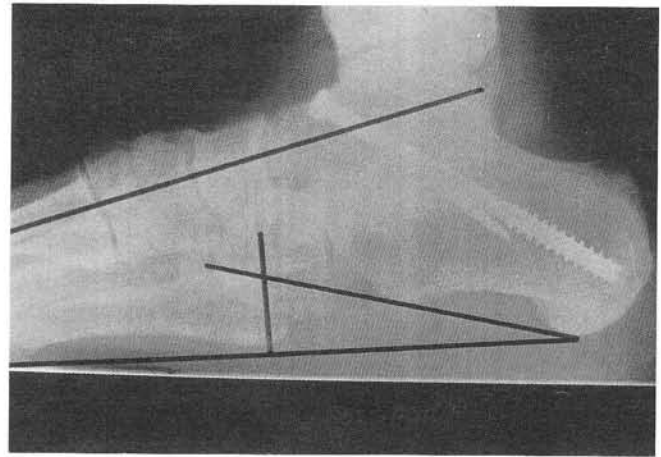


Figure 2D. Lateral view, 13 months postoperative.

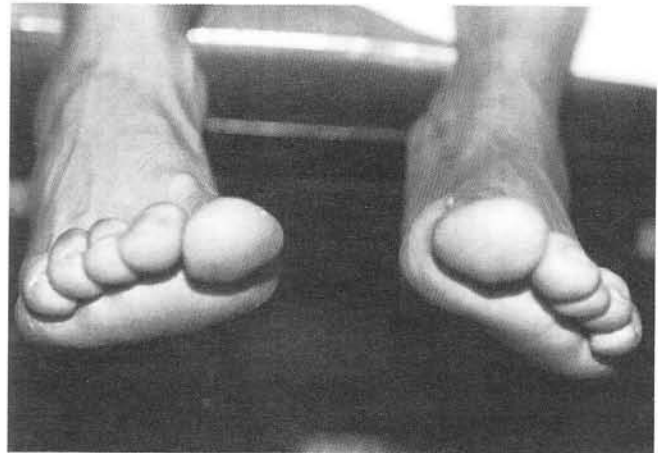


Figure 2E. Clinical photograph demonstrating the residual forefoot varus alignment following the subtalar joint arthrodesis. A custom orthotic device has controlled this. Surgical correction was not necessary, although the patient was advised that a subsequent medial column osteotomy or fusion might be necessary in the future.

The surgeon must also evaluate and study the forefoot to rearfoot relationship prior to performing an isolated subtalar joint arthrodesis for correction of a flatfoot deformity. The presence of a significant varus or supinatus deformity of the forefoot may mandate a medial column osseous or soft tissue stabilization procedure. Examples of such procedures include a modified Young's tenosuspension, peroneus brevis to longus anastomosis, medial cuneiform plantarflexory osteotomy or arthrodesis of one or more of the medial column joints. In mild to moderate cases, the senior author has not performed such procedures, but chosen to accommodate such deformities with accommodative custom orthotic devices with very good

success (Figs. 3A-3E). It is rare that medial column procedures need to be performed in spite of the clinical observation of residual inversion of the forefoot on the rearfoot. Obviously, in more severe cases such procedures are necessary to achieve a successful clinical outcome. Failure to accommodate or correct such deformities may place undue stress on the ankle joint, resulting in strain of the medial ligamentous tissues (i.e. deltoid ligament) and ultimately result in valgus deformity of the ankle joint (Fig. 4).

Perhaps the most controversial aspect of performing an isolated joint arthrodesis for correction of an acquired flatfoot deformity is deciding which joint(s) should be fused and which

should be preserved. Presently, there are advocates of isolated talonavicular joint arthrodesis or isolated calcaneocuboid arthrodesis with an interposition bone graft in lieu of subtalar joint arthrodesis. One of the rationales for avoiding fusion of the subtalar joint is the need to preserve motion in this joint for shock absorption and adjusting to uneven terrain. However, there is limited conclusive evidence that performing an isolated midtarsal joint arthrodesis in fact preserves a sufficient amount of motion that will be of clinical relevance and benefit to the patient. Perhaps part of the reluctance to performing an isolated subtalar joint arthrodesis is psychological in nature. The subtalar joint has always been appreciated as the major translator of motion between the foot and leg, acting somewhat as a universal joint does in automobiles. Although the talonavicular joint is considered part of the midtarsal joint complex, its anatomic and functional relationship with the subtalar joint is more intimate. Any alteration or manipulation of the talonavicular joint significantly impacts the subtalar joint.

There is also considerable interest in the podiatric community over the use of joint preservation procedures such as subtalar joint arthroereisis, Evan's calcaneal osteotomy with bone grafting, and medial column procedures alone or in combination with calcaneal osteotomy. The authors feel that these procedures certainly warrant careful consideration in patients who do not present with severe peritalar subluxation, but should be used with caution in more severe cases. Until further data are reported, the ultimate decision will be based upon a combination of factors, including the personal experience and philosophy of the surgeon.

While isolated subtalar joint arthrodesis can very successfully correct peritalar subluxation and restore a foot to a neutral attitude, thereby relieving pain and instability, there are certain clinical implications that deserve discussion with patients undergoing this procedure. Patients may demonstrate varying degree tolerance to the "frozen" joint. A patient whose occupation is reliant upon ambulating on uneven ground surfaces may be intolerant of subtalar joint arthrodesis or any other single, double or triple joint fusion procedure. The classic example is the person who works on the deck of a ship, or on gravel, sand, or

sod surfaces. Appropriate orthotic devices with shock absorption capability will be beneficial in such patients.

Historical observations and extensive clinical experience of rearfoot fusions have been the stimulus for further clinical study and research in the art of rearfoot fusions, especially isolated subtalar joint arthrodesis. It is hoped that the author's present study will play a role in refining the contemporary practice of rearfoot fusions for the purpose of correcting the adult acquired flatfoot deformity.

Finally, the authors wish to emphasize that triple arthrodesis continues to play an important role in the correction of the pes valgo planus foot deformity. It is considered the procedure of choice in cases where there is severe rigidity to the deformity, significant alteration of the normal architecture of the tarsal bones, or significant arthritic changes involving the midtarsal and/or subtalar joint complexes. The preoperative neutral position x-rays are very helpful in assessing these factors and should compliment the clinical findings. It is the summary of findings that ultimately determines whether a subtalar joint fusion will suffice instead of a triple arthrodesis.

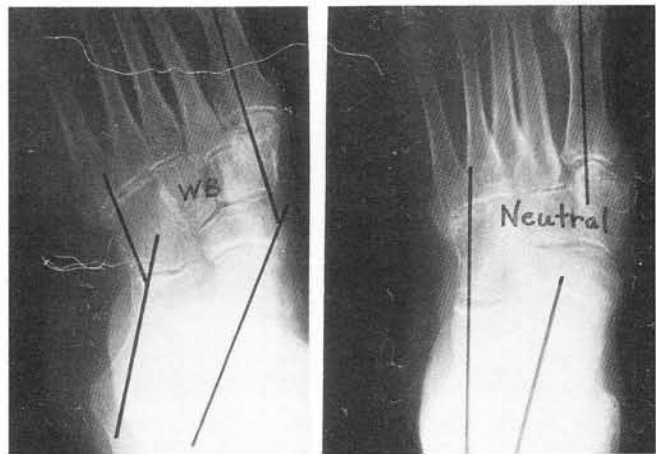


Figure 3A. Dorsal plantar weight-bearing and neutral position radiographs in a very active 73-year-old patient with end stage peritalar subluxation secondary to long standing tibialis posterior tendon dysfunction. Secondary changes are seen throughout the medial column articulations and even the tarsometatarsal articulations, however, the neutral position film demonstrates excellent restoration of alignment. Clinically, the midtarsal joint had excellent motion without pain or crepitus. A large callus beneath the medial column was a primary symptom making any type of orthotic or brace intolerable in this patient.

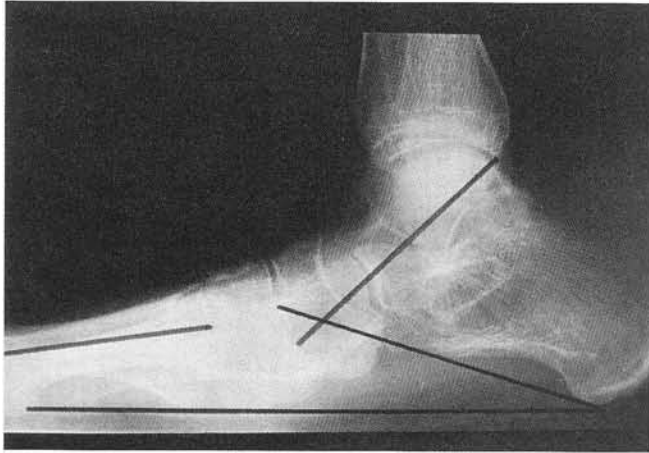


Figure 3B. Lateral weight bearing radiograph. This view would suggest the need for a triple arthrodesis at the very least to achieve satisfactory restoration of alignment to the rearfoot and midfoot areas.

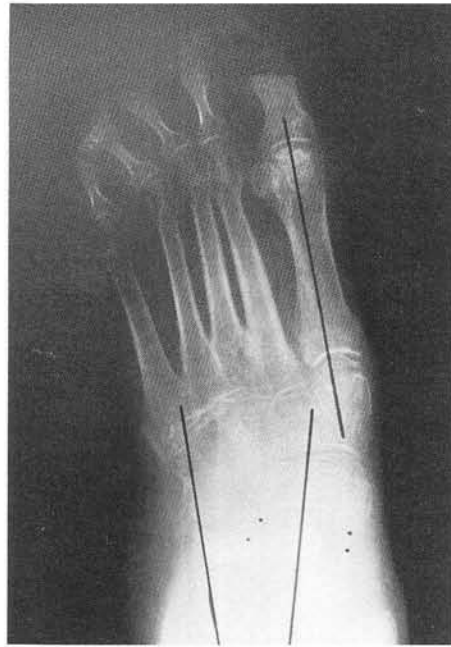

Figure 3C. Dorsoplantar weight bearing radiographs taken several months postoperatively. Note the excellent correction of the peritalar subluxation shown in figure 3A.

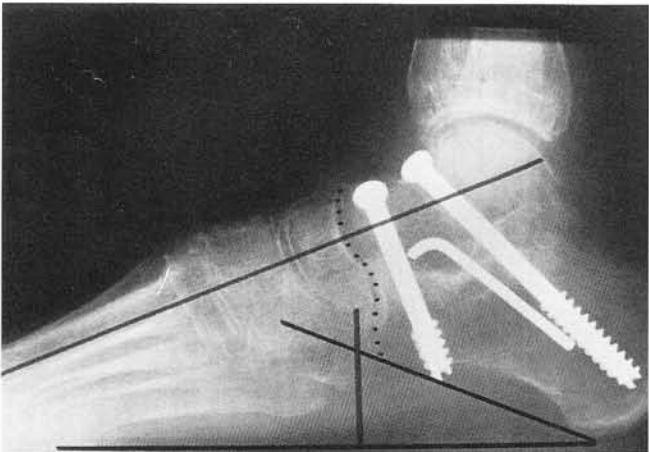


Figure 3D. Lateral weight bearing radiograph taken several months postoperatively. Note the excellent correction of the deformity in contrast to figure 3B. The dorsal prominence at the Lisfranc articulation is clinically prominent and may require surgical resection in the future.

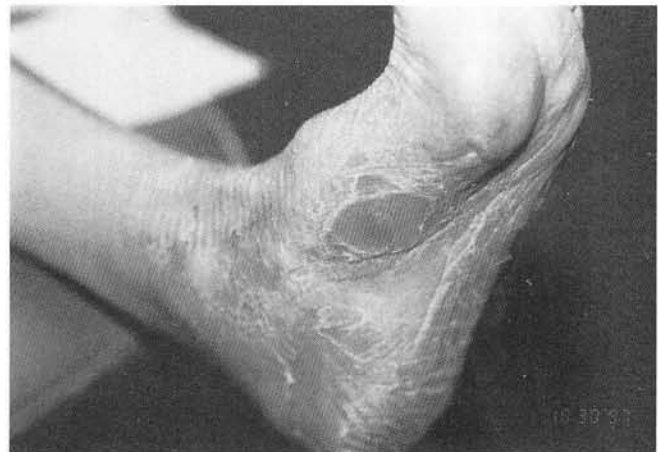

Figure 3E. Clinical photograph shortly after institution of weight bearing. Note the residual tyloa in the medial column which is resolving as a result of restoration of alignment of the subtalar joint without any concomitant procedure in the medial column.

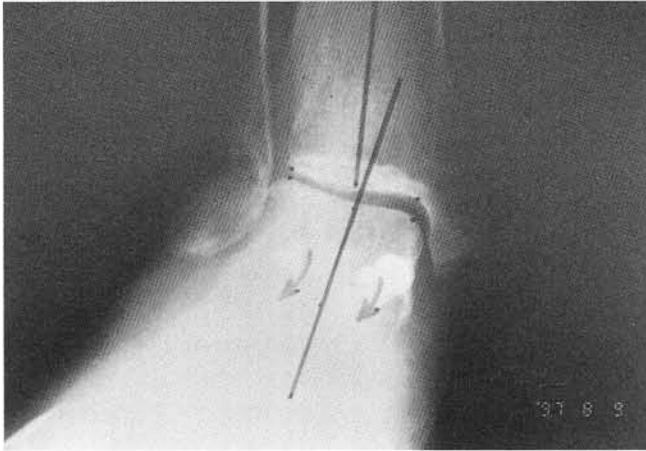


Figure 4. Anteroposterior ankle radiograph demonstrating early valgus stress following primary subtalar joint arthrodesis for an adult flatfoot syndrome.

SUMMARY

In 1994, the authors reported the results of a limited retrospective review of 19 patients involving 21 feet (Subtalar Joint Arthrodesis: A Retrospective Study; Yu, Shook, Seller and Judge). The current data includes the results of that review along with the results of an additional 25 patients (27 feet). The composite data provide convincing evidence that an isolated subtalar joint arthrodesis can be performed in lieu of a triple arthrodesis, and is extremely effective in restoring a neutral rearfoot and midfoot complex in patients with a severe collapsing pes valgo planus deformity. While success of the procedure is dependent on many variables, the most important one appears to be restoration of the joint to its neutral attitude.

Significant changes can be expected with respect to the intertarsal joint relationships of the talus, calcaneus, navicular and cuboid as a result of restoring the proper alignment and position of the calcaneus beneath the talus. To the authors' knowledge, this is the only retrospective radiographic evaluation which has demonstrated the efficacy of a single joint arthrodesis to realign a foot with significant peritalar subluxation. The authors feel that subtalar joint arthrodesis should be considered in lieu of triple arthrodesis in patients with severe but flexible collapsing pes valgo planus deformity in the absence of degenerative arthritic changes, and where a joint preservation procedure is not indicated.

BIBLIOGRAPHY

- Beaty JH: Paralytic disorders. In Crenshaw AH, ed. *Campbell's Operative Orthopedics* St. Louis, MO; Mosby-Yearbook:1992;2383.
- Caldarella DJ, Banks AS: Selective arthrodesis of the subtalar joint. In Vickers NS, Ruch JA, eds. *Reconstructive Surgery of the Foot and Leg, Update 92* Tucker, Ga; Podiatry Institute Publishing.:1992;56-57.
- Caldwell GA: Arthrodeses of the feet. *Instr Course Lect* 6:174:1949.
- Crego CH JR, McCarroll HR: Recurrent deformities in stabilized paralytic feet. *J Bone Joint Surg* 20:609, 1938.
- Cowell HR: Pes planus. In Everts CM, ed. *Surgery of the Musculoskeletal System* New York; Churchill Livingstone: 1983;9,59.
- DiNapoli R, Ruch JA: Triple arthrodesis and subtalar joint fusions. In McGlamry Ed, Banks AS, Downey MS, eds. *Comprehensive Textbook of Foot Surgery* 2nd ed, Baltimore, Md; Williams & Wilkins:1992;1040-1075.
- Gould N: Trephining your way. *Orthop Clin N Am* 4:157, 1973.
- Grice DS: An extra-articular arthrodesis of the subastragal joint for correction of paralytic flat feet in children. *J Bone Joint Surg* 34A:927:1952.
- Grice DS: Further experience with extra-articular arthrodesis of the subtalar joint. *J Bone Joint Surg* 37A:246,1955.
- Hallgrímsson S: Studies on reconstructive and stabilizing operations on the skeleton of the foot. *Acta Chirur Scan* :1943.
- Hatt RN: The central bone graft in joint arthrodesis *J Bone Joint Surg* 22:393, 1940.
- Leavitt DG: Subastragaloid arthrodesis for the os calcis type of flatfoot. *Am J Surg* 59:501, 1943.
- Mann RA, Morris B: Subtalar fusion for isolated subtalar disorders, preliminary report. *Clin Orthop Rel Res*
- Patterson RL, Parrish FF, Hathaway EN: Stabilizing operations on the foot, a study of the indications, techniques used and end results. *J Bone Joint Surg* 32A:1, 1950.
- Richardson EG: Pes planus. In Crenshaw AH, ed. *Campbell's Operative Orthopedics* St. Louis, Mo; Mosby-Year Book:1992:2693.
- Russotti GM, Johnson KA: Isolated talocalcaneal arthrodesis, a technique using moldable bone graft. *J Bone Joint Surg* 70A:1472, 1988.
- Schwartz RP: Arthrodesis of subtalar and midtarsal joints of the foot. Historical review, preoperative determinations and operative procedure. *Surgery* 5:619, 1946.
- Scott SM, James PC, Stevens PM: Grice subtalar arthrodesis followed to skeletal maturity. *J Ped Orthop* 8:176:1988.
- Soren A: Safe inlay of bone graft in arthrodesis *Clin Orthop Rel Res* 58:147,1968.
- Willard DP: Subastragal arthrodesis in lateral deformities of paralytic feet. *Am J Orthop Surg* 14:323, 1916.
- Yu GV: Rearfoot arthrodesis, the podiatry institute technique. In Vickers NS, ed. *Reconstructive Surgery of the Foot and Leg, Update 96* Tucker, Ga; Podiatry Institute Publishing:1996;20-29.
- Yu GV: Curettage technique for major rearfoot fusions. In Camasta CA, Vickers NS, Ruch JA eds. *Reconstructive Surgery of the Foot and Leg, Update 93* Tucker, Ga; Podiatry Institute Publishing:1993;260-267.
- Yu GV: Subtalar joint arthrodesis. In Dinapoli R, ed. *Reconstructive Surgery of the Foot and Leg, Update 90* Tucker, Ga; Podiatry Institute Publishing:1990;20-25.