

# CHRONIC VENOUS INSUFFICIENCY WITH ULCERATION: Review of the Literature and Treatment Recommendations

*Gage M. Caudell, DPM*

*Molly S. Judge, DPM*

*Adam M. Budny, DPM*

*Subail B. Masadeh, DPM*

*Bonnie Lin, DPM*

## INTRODUCTION

An estimated 25% of the United States population has chronic venous insufficiency (CVI).<sup>1</sup> Of equal importance is the fact that this involves a much younger population than do other more commonly described disease processes such as arterial occlusive disease and simple varicose veins, which receive much more attention in the medical community. CVI, when severe, frequently results in ulceration that can lead to significant morbidity. Left untreated, patients predictably experience leg pain, edema, dermopathy, and ultimately ulceration. Venous ulcerations have a prevalence between 1-5% in westernized nations.<sup>1</sup> It is important to realize that CVI with ulceration is vastly different than straight forward varicose veins and as such the prevalence of CVI is reported distinctly in the medical literature. Compression therapy is the gold standard for treating this condition, and over time a variety of methods have proven effective for reducing edema and resolving superficial ulcerations. When ulceration is present, adjunctive therapies such as local wound care, topical wound healing agents, chemical debridement, and surgical debridement each have shown various degrees of efficacy. The goal of this article is to provide clinicians with the background to diagnose CVI and to select the most appropriate therapy.

## GROSS ANATOMY

The anatomy of the venous circulation within the lower extremity is complex in its arrangement of vessels and one-way valves influencing venous blood flow. This arrangement is not unlike the chambers of the heart where there is a combination

of muscular pump action and passive flow that maintains optimal circulation within the system. The venous systems flow from the very distal lower extremity into a proximal conduit within the abdominal cavity. More specifically, there are 2 systems of venous structures that return deoxygenated blood to the heart, a deep and a superficial system. The deep venous system consists of numerous calf veins that return oxygen depleted blood to the popliteal vein via the anterior and posterior tibial veins. The popliteal vein advances blood to the femoral vein and then on to the iliac vein where blood is siphoned into the inferior vena cava (IVC). The inferior vena cava is the primary conduit that transports deoxygenated blood from the abdomen through the diaphragm and into the right atrium of the heart. This deep venous system is considered a high pressure system given the muscular pumping action of the calf muscle.

The superficial venous system, a low pressure system, begins anterior to the medial malleolus and is composed of the longest vein in the body; the great saphenous vein. A continuation of the medial marginal vein, the great (long) saphenous vein will join the femoral vein at a natural defect in the inguinal fascia; the foramen ovale. In approximately 10% of cases a duplication of the great saphenous vein can be seen between the knee and the foramen ovale, using duplex imaging.<sup>2</sup> Throughout its superficial course, the great saphenous vein is associated with numerous cutaneous nerves; specifically the medial femoral cutaneous nerve in the thigh, the infra patellar nerve branches about the knee and the saphenous nerve along the medial leg.<sup>3</sup> One further anatomic fact about the great saphenous vein is that it has



only 10-20 valves throughout its entire length, the majority of which lie in the leg.<sup>4</sup> The short or lesser saphenous vein runs lateral to the Achilles tendon. In two-thirds of cases it extends toward the midline where it penetrates the deep fascia between the heads of the gastrocnemius muscle within the popliteal fossa and empties into the popliteal vein above the knee. In one-third of cases the lesser saphenous vein may join the greater saphenous vein in the upper thigh region.<sup>5</sup>

The deep system is separated from the superficial system by muscular fascia where perforating veins provide communication between the two. These perforating (communicating) veins are equipped with one-way valves that preserve the proximal transport of venous blood toward the heart. There are 3 medial perforating veins, with the most abundant supply of these perforators located behind the medial malleolus lying over the posterior tibial vein; the lower perforating vein. The middle-perforating vein rests 7-10 cm proximal to the ankle and lies posterior to the tibia. The superior perforating vein is located within the proximal one-third of the calf and rests posterior to the tibia (Figure 1). The location of the perforating veins is important to understand as this system of veins is the source of dysfunction in a majority of cases.

## FUNCTIONAL ANATOMY

The cardiac system with its arterial and venous components is a natural parallel to the venous system as it also consists of a muscular pump and a passive venous return system. The venous system is broadly composed of a high pressure, deep system and a low pressure, superficial system. The perforating veins allow communication between the 2 systems as they assist in propagation of deoxygenated blood toward the heart. Contraction of the calf muscle increases pressure in the deep system driving blood proximally while the one way valves of the perforators, like the cuspid valves in the heart, prevent the retrograde flow of fluid into the low pressure (superficial) system. Relaxation of the calf muscle allows blood to be aspirated from the superficial system into the deep system via the open valves of the perforating veins. If the perforating valves are weakened or are insufficient to prevent the retrograde flow of blood during systole, as the calf muscle pumps, this high pressure

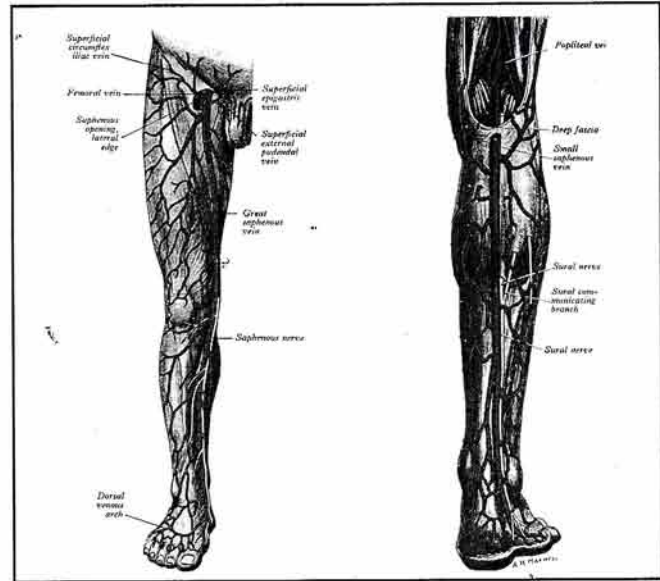


Figure 1. Illustration demonstrating the anatomy of the great saphenous vein (Illustration adopted from Gray's Anatomy 37th Edition: Angiology: Veins of the lower limb, edited by Peter L. Williams, Longman Group UK Limited 1989, FYI Pg.812).

pushes blood back into the superficial system causing a dilation of venous structures and later results in the stagnation of flow. It is this venous dilation and stagnation of flow that creates varicosities, which result in localized tissue hypoxia, dermopathy, and the development of ulcerations. Of clinical importance, the cutaneous nerves associated with the great saphenous vein can become irritated as a consequence of local tissue hypoxia and toxicity due to chronic venous insufficiency prompting common clinical complaints such as aching and dull pain of the thigh and calf.

## PATHOGENESIS

The cause of CVI and ulceration involves damage to the blood vessels leading to focal ischemia, inflammation, and vascular infiltration. Currently there are 2 popular theories as to why this occurs. The Fibrin Cuff theory suggests that there is an increase in macromolecule leakage through the vessels secondary to an increased venous pressure. This blockade of macromolecules subsequently creates a barrier to diffusion of oxygen and nutrients.<sup>6,7</sup> An alternate hypothesis for the development of CVI with ulceration is the White Cell Trapping Theory. This theory postulates that leukocytes become entrapped in the capillaries and subsequently are activated by venous hypertension



causing tissue destruction.<sup>7,8</sup> The degree of destruction is typically associated with the severity of the venous insufficiency. Regardless of the theory, the underlying theme in CVI with ulceration is increased venous hypertension in the presence of incompetent superficial or deep system valves resulting in a leakage of macromolecules, activation of inflammatory mediators, entrapment of growth factors, the development of local ischemia and finally ulceration.

## DIAGNOSIS

Although lower extremity ulcerations can be caused by pressure, peripheral arterial disease, and various dermatological disorders, CVI is a distinct entity that has a signature clinical presentation. The symptoms of CVI with or without ulceration may include but are not limited to pain, chronic muscle fatigue of the

thigh and or calf, and muscular spasms in the posterior muscle groups of the thigh and leg as well as the intrinsic muscles of the arch. The outward signs of CVI will vary with the severity of the condition and include: lower extremity edema, scaling and cobblestoning of the skin, hyperpigmentation (e.g., hemosiderin deposits), varicosities, and lipodermatosclerosis (Figures 2-4).<sup>9</sup> Patients may relate a history of previous deep vein thrombosis. Ulceration on or near the medial malleolus is a common clinical finding associated with end stage incompetence of the great saphenous vein (Figure 5). Signature characteristics of venous ulcers include superficial dermal defects with irregular, flat, or slightly steep borders about a granular base.<sup>10</sup> Signature characteristics of venous ulcers include superficial dermal defects with irregular, flat, or slightly steep borders about a granular base, and drainage.<sup>10</sup> The steep border of these wounds is due

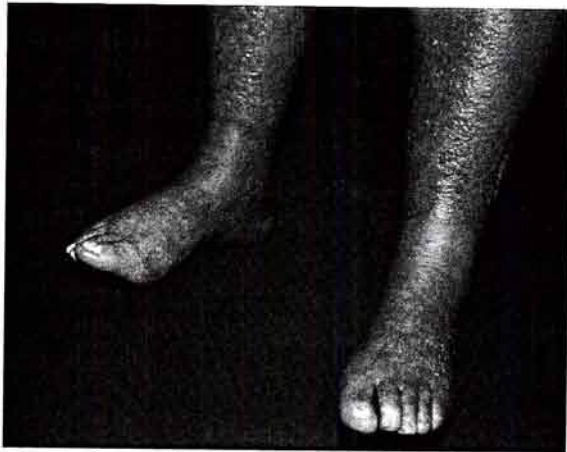

Figure 2. Clinical appearance of patient with CVI with lichenification and thickening of the skin (cobblestone skin).

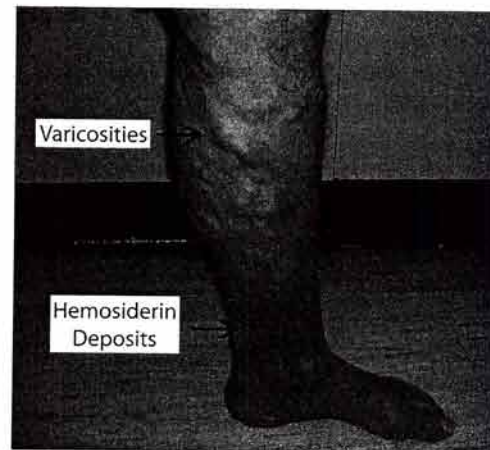


Figure 3. Clinical appearance of patient with previous surgery of the ankle with resultant painful varicosities and hyperpigmentation (hemosiderin deposits).

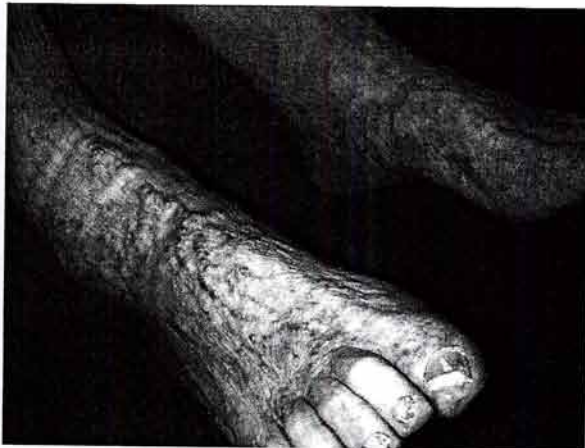

Figure 4. Clinical appearance of multiple small varicosities of the foot and engorgement of the medial marginal and great saphenous vein.

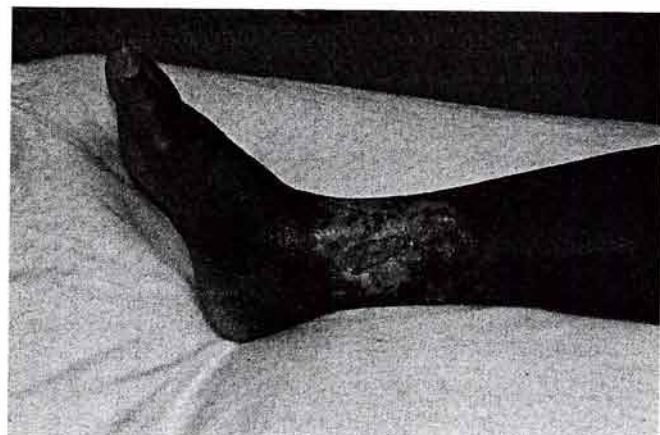

Figure 5. Clinical appearance of CVI with full thickness ulceration at the medial ankle. The patient presented with hypopigmentation around wound, irregular border, and fibrotic base. The wound was treated with iodisorb and Unna's boot.



to chronic edema as it causes lichenification of the skin giving the affected area a cobblestone appearance. These ulcers are not painful as opposed to their arterial counter parts. Arterial ulcers can be exquisitely sensitive and ischemic ulcers often require pain management in addition to local wound care. In CVI thigh or calf pain is not due to the condition of the wound but rather is the result of venous hypertension and its ill effect on local structures such as muscles and nerves.

When CVI is in question it is recommended that the patient undergoes duplex ultrasonography to identify the location and extent of valvular insufficiency.<sup>11,12</sup> It is important when ordering this test that you indicate that you want to evaluate for venous reflux. When the test is ordered specifying evaluation for venous reflux, both the superficial and deep venous system are examined.<sup>9,12</sup> When there is a question as to the nature of the vascular dysfunction other non-invasive testing is completed including pulse volume recordings (PVR), ankle brachial indexes (ABI), digital photo plethysmography (PPG) and transcutaneous oxygen pressure (TCPO<sub>2</sub>) measurements, and laser Doppler skin perfusion pressure.

An ABI of <0.8 is suggestive of severe arterial insufficiency and requires immediate vascular consultation. Compression therapy is contraindicated in the face of significant arterial dysfunction and proper revascularization takes precedence in this event.<sup>13,14</sup>

## MALIGNANCY

Any long standing venous ulceration that has not shown signs of improvement during 3 months of local wound care should be suspect for malignancy and a biopsy is in order.<sup>15</sup> Even though rare, both basal cell and squamous cell carcinoma can manifest in these wounds. Squamous cell carcinoma, which has the higher incidence in venous ulcerations, can be aggressive leading to metastasis and eventual death.<sup>9</sup>

## TREATMENT

### Compression Therapy

Edema therapy is the mainstay in addressing CVI. There are numerous options when selecting a modality to provide compression therapy. Although many are effective in reducing edema, multilayer dressings have shown demonstrable

superiority over single layer dressings.

For years Unna's boot dressing was the treatment of choice, but over the past 10 years the use of multilayer compression dressings have taken the forefront in CVI therapy. Unna's boot dressing does not provide compression but rather removes edema by taking advantage of the action of the calf muscle pump against a restrictive layer of fibrous material.<sup>9</sup> Therefore in patients who are inactive or nonambulatory, an Unna's boot dressing is not effective edema therapy.<sup>7</sup> The optimal amount of compression needed in treating CVI is 25 to 40 mm Hg and such devices can be obtained over-the-counter.<sup>9</sup>

Multilayer compression bandages such as Profore (Smith & Nephew, Largo, FL), Setopress (Seton Healthcare Group, UK), and Dynaflex (Johnson & Johnson, Piscataway, NJ) have been shown to decrease lower extremity edema and help to resolve venous ulcerations in less time as compared with compression stockings, single layer dressings, or therapy without compression devices. These bandages typically consist of an absorbent layer next to the skin and 1 or 2 elastic layers with an additional self-adherent compressive shell (Figure 6). Another device that has proven efficacy

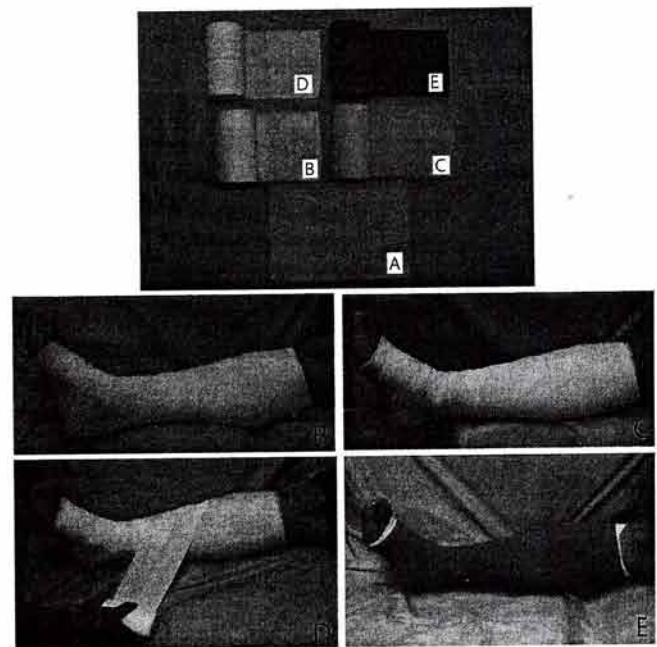


Figure 6. The Profore (Smith & Nephew) multilayer dressing is a commonly used compression device. The device consist of A) a non-adherent layer, placed over the wound. Next B) an absorbent layer is applied to help in drying the wound(s). Compression is initiated, first with an C) absorbent compression layer, and then D) an elastic compression layer, applied using a figure 8 technique. Last a E) final self adherent shell is applied to maintain the internal layers and to add additional compression.



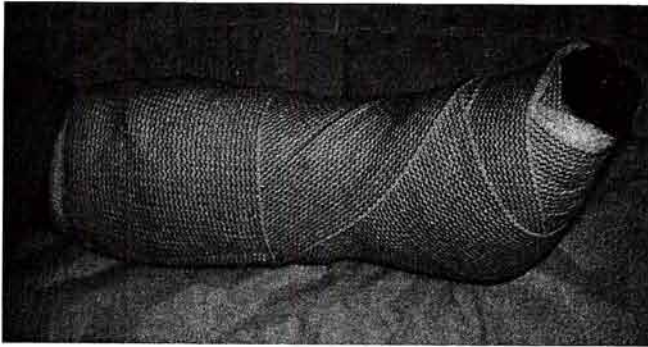


Figure 7. Clinical appearance of 3-layer Jones compression dressing.

is the three-layer Jones compression bandage. Each layer consists of 2 rolls of Specialist cast padding (Johnson & Johnson, Raynham, MA) and a 6-inch ace wrap. Alder et al determined that this device can provide a total compression of 27 mm Hg (Figures 7, 8).<sup>17</sup>

The Cochrane Group completed a meta-analysis of the literature consisting of 22 trials comparing the effects of different compression therapy. They concluded that compression therapy increased ulcer healing rates when compared with no compression. High compression multilayered dressings were also found to be more effective than low compression single-layer dressings for healing CVI ulcerations.<sup>18</sup>

### Local Therapy

Topical dressings can assist in decreasing bacterial count, debride fibrotic tissue, promote a moist environment, and facilitate healing. Silvadene (King Pharmaceuticals, Bristol, TN), Iodosorb (Healthpoint, Fort Worth, TX), and Accuzyme (Healthpoint, Fort Worth, TX) are just a few therapies on the market that can assist in the treatment of venous ulcers, but there is little data to show if used alone they speed healing. Most researchers agree these local dressings should be used only as an adjunct to compression therapy and not as a solo form of ulcer care.<sup>9</sup>

There are some common local wound care strategies that are suggested and are practical for use in the clinic or home settings. If these regimens are simple to perform and are inexpensive, patient compliance may be enhanced and clinical cure is much more likely to result. Local wound care should be modified based upon the clinical appearance of the wound. Should the wound appear moist with a beefy red granulation tissue then simple wet to dry dressings using 0.9% NaCl will be satisfactory. This type of wound bleeds well with debridement

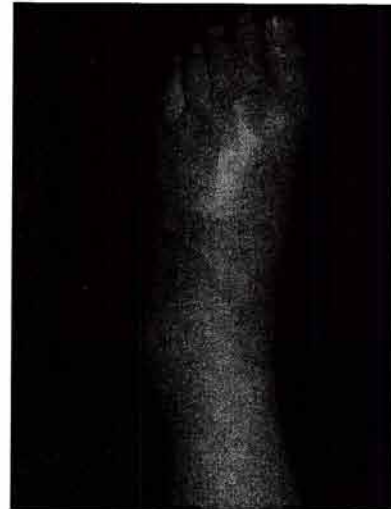

Figure 8A. Clinical appearance of before and (8B) after utilization of Jones compression dressing.

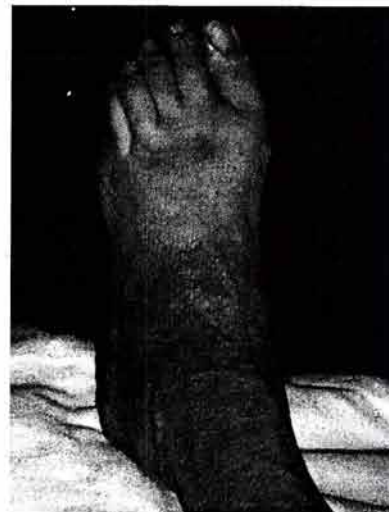

Figure 8B.

given the neovascularity of the granulation tissue and so does not require any special topical agents to achieve wound healing. These dressing are typically changed 2-3 times per day for best results. If the care plan does not include aggressive edema control, a weeping dermatitis often develops and mandates the use of a drying agent such as 0.5% sodium hypochlorite (Dakins solution). Caution is necessary when using this agent as concentrations higher than 0.5% may inhibit angiogenesis, impair wound healing and may result in irritation or even burn injury to the skin. This agent will bleach hair and clothing so care should be taken to apply directly to the affected area only. If an ulcer appears to be colonized by pseudomonas, a 3% Boric acid solution



should be used in lieu of normal saline to eliminate the gram negative rods and provide a healthier wound bed for granulation tissue in-growth. In the event that fibrinous tissue in-growth is evident, an alternate strategy is required as a simple wet to dry dressing will not halt this adverse progression. When this yellow, fibrous tissue is present in the base of a venous ulcer benzoyl peroxide under occlusion will prove sufficient to eradicate fibrinous ingrowths and allows perpetuation of healthy granulation tissue. This dressing should be prepared by applying a piece of gauze measuring the same size as the center of the ulcer. A few drops of 10% benzoyl peroxide are applied to the gauze and is covered by a piece of plastic wrap (Saran or other cling wrap). With the benefit of this occlusive covering the benzoyl peroxide is protected from evaporation and absorption into the dressing. This occlusion technique drives the agent deep into the affected tissue and provides a full potency agent to break down the fibrous tissue. The frequency of these dressing changes are no different than for other wet to dry dressings and changing q8h is suggested. When the quality of the skin has suffered from chronic edema, thickened verrucial or cobblestone appearance can be reversed with the benefit of potent emollient agents such as 12% ammonium lactate. Should a frank dermatitis develop in association with chronic venous stasis topical hydrocortisone cream/ointment should be used and is commonly applied 2-4 times per day for best results. It cannot be over stated that compression therapy is an integral component of any wound care plan and the patient must understand that compression devices are a life long therapy for chronic venous insufficiency.

### Systemic Therapy

Three pharmacologic agents in various trials have shown effectiveness in resolving wounds associated with CVI, especially when used concurrently with compression therapy. Aspirin 300 mg was shown to be effective in ulcer healing in a double-blind randomized clinical trial involving 20 patients.<sup>19</sup> The number of ulcers healed at 4 months with the benefit of compression and ASA was higher than compression and placebo. The authors concluded that aspirin should be used as an adjunct in treatment. The authors could not determine the exact mechanism of how aspirin assist in healing CVI ulcerations.<sup>19</sup> This study was limited by a small study group and results were based on a specific

size of the wound and not complete resolution.

Horse chestnut seed extract (HCE) in several placebo-controlled trials has shown improvement in CVI as compared with placebo. HCE stimulates the release of PGF<sub>2</sub>-alpha (F series prostaglandin), which induces vasoconstriction and reduces the ill effects of venous congestion. This results in a decreased venous permeability and reduces the extravasation of low molecular proteins, water, and electrolytes. In one study, 50 mg of escin (the active form of HCE) twice daily was equivalent to compression stockings.<sup>20</sup>

Pentoxifylline has been shown to be effective in ulcer healing when combined with compression therapy. Pentoxifylline increases erythrocyte (RBC) flexibility and has an inhibitory effect on RBC adhesion that may reduce the release of proteolytic enzymes that damage tissue as stated in the white cell theory.<sup>13</sup> Jull et al in 2002 published a review of all randomized controlled trials using pentoxifylline for venous ulcers. Pentoxifylline was shown to provide added benefit when used in conjunction with compression therapy and may possibly be efficacious as monotherapy.<sup>13</sup> One study suggested high dose pentoxifylline (2,400mg daily) was better at increasing healing time as compared to low dose (1,200mg daily) therapy.<sup>21</sup> The most common side-effect reported in both studies was gastrointestinal disturbance and this was no different than with placebo.

### Surgical Treatment

Surgical treatment is most often unnecessary in the treatment of venous ulcers. If significant fibrous non-viable tissue is present, aggressive debridement is required. If the ulcer is too sensitive for in office debridement and autolytic agents have proven unsuccessful (or are not tolerated by the patient), surgical debridement may be indicated. Traditional surgical debridement utilizing dermal curettes can be successful, however new technologies and advances in wound debridement have been developed. One such device is the VersaJet Hydrosurgery system (Smith & Nephew, Largo FL), which allows precise removal of fibrotic tissue and debris. All non-viable tissue should be removed until a granular bleeding bed is present.

Plastic surgery consisting of autologous skin graft has been studied in the treatment of non-healing venous ulcers. Twelve-month healing rates have been reported as high as 74% and recurrence



rates between 28-95%.<sup>22</sup> Kjaer et al reported a 1-year healing rate of 53% with meshed split-thickness skin graft. More importantly, they showed that Diabetes mellitus, initial ulcer size, minor local venous surgery, compression noncompliance, and insufficiency in the popliteal vein was associated with increase healing time, non-healing, and recurrence.<sup>22</sup>

Bioengineered grafts have also been indicated in the treatment of venous ulcers. Apligraf (Organogenesis, Canton, MA), Integra (Integra Lifesciences, Plainsboro, NJ), and GammaGraft (Promethean Health Sciences, Pittsburgh, PA) have been approved by the FDA for use in venous ulcers. Falanga et al, in a controlled clinical trial, studied patients with venous ulcers who received compression or compression plus the bilayered skin equivalent. A greater percentage of patients healed with the skin equivalent and the time to healing was 3-times faster.<sup>23</sup> Among venous ulcer patients, those with refractory wounds of greater than one year, the skin equivalent, used with compression dressings, was 2 times more effective at complete closure when compared to compression therapy alone.<sup>24</sup>

The Cochrane Group examined all randomized controlled trials of skin grafts in the treatment of venous leg ulcers in the literature and concluded that bilayer artificial skin (e.g., Apligraf) when used in conjunction with compression bandaging, increases the chance of healing a venous ulcer as compared with compression and a simple dressing. They underlined the need for further research to assess the effectiveness of other forms of skin grafts, including autografts and allografts.<sup>25</sup>

## LONG-TERM TREATMENT

Once healing has been achieved, long-term use of compression stockings is necessary to prevent recurrence. It has been reported that 78-100% of patients who do not wear compression stockings will have recurrence of CVI ulcerations. It is important to educate patients on the importance of these devices and that they constitute long term treatment not just temporary care.<sup>10</sup> The Thrombo Embolic Device (TED), commonly used in hospitals, only exert 8 to 10 mm Hg of pressure at the ankle and may be beneficial in the prevention of deep venous thrombosis, but are not effective in chronic venous insufficiency. It is recommend that 25-40 mm Hg of pressure is needed for CVI prevention.<sup>9</sup> In

more severe cases custom made compression hose may be required and are considerably more expensive. While it is unfortunate, custom fit devices are often cost prohibitive and this has a negative impact on patient compliance.

## CONCLUSION

Chronic venous insufficiency with ulceration is associated with increased morbidity and has a negative impact on the quality of life. Treatment begins with the proper diagnosis and this is best achieved in addition to ruling out other culprits of ulceration such as ischemia. Understanding the mechanics of chronic venous insufficiency and identifying the location and extent of valvular insufficiency is paramount to successful management of this disorder. Successful treatment consists of patient education, local wound care and compression therapy. Multilayer compression dressings have been shown to decrease edema and improves healing time. Systemic therapy consisting of aspirin, horse chestnut seed extract, and pentoxifylline has shown some success in wound healing but more research is needed. Educating patients about chronic venous stasis, its potential complications and the need for long term treatment are necessary to prevent recurrence.

## REFERENCES

1. Baker SR, Stacey MC, Jopp, McKay AG, et al. Epidemiology of chronic venous ulcers. *Br J Surg* 1991;78:864.
2. Leather RP, Kupinski AM. Preoperative evaluation of the saphenous vein as a suitable graft. *Semin Vasc Surg* 1988;1:51.
3. Williams PL. Gray's Anatomy 37th Edition: neurology: the femoral nerve. Longman Group: UK ; 1989. p. 1142.
4. Williams PL. Gray's Anatomy 37th Edition: angiology: veins of the lower limb. Longman Group: UK; 1989. p.812.
5. Kosinski C. Variations of the external saphenous vein. *J Anat* 1926;60:131
6. Browse NL, Burmand KG. The cause of venous ulceration. *Lancet* 1982;2:243-5.
7. Falanga V. Care of venous leg ulcers. *Ostomy/Wound Management* 1999;45:33S-42S.
8. Van de Scheur M, Falanga V. Pericapillary fibrin cuffs in venous disease: a reappraisal. *Dermatol Surg* 1997;23:955-9.
9. Brem H, Kirsner R, Falanga V. Protocol for the successful treatment of venous ulcers. *Am J Surg* 2004;188:1S-8S.
10. Trent TT, Falabella A, Eaglstein WH, Kirsner RS. Venous ulcers: pathophysiology and treatment options: Part 1 and 2. *Ostomy/Wound Management*. 2005;51:38-54.
11. Peripheral Vascular Diseases: Edited Young JR, editor. St. Louis: Mosby-Year Book; 1991.
12. Min RJ, Neil MK, Golia P. Duplex ultrasound evaluation of lower extremity venous insufficiency. *J Vasc Interv Radiol* 2003;14:1233-41.
13. Jull A, Waters J, Arroll B. Pentoxifylline for treatment of venous leg ulcers: a systematic review. *Lancet* 2002;359:1550-4.
14. Strandness DE Jr, Schultz RD, Sumner DS, Rushmer RF. Ultrasonic flow detection: a useful technic in the evaluation of peripheral vascular disease. *Am J Surg* 1967;113:311-20.

15. De Araujo T, Valencia I, Federman DG, Kirsner RS. Managing the patient with venous ulcers. *Ann Intern Med* 2003;138:326-34.
16. Nelson EA. Compression bandaging in the treatment of venous leg ulcers. *J Wound Care*. 1996;5:415-8.
17. Yu GV, Schubert EK, Khoury WE. The Jones compression bandage: review and clinical applications. *Journal Am Podiatr Med Assoc* 2002;92:221-31.
18. Cullum N, Nelson EA, Fletcher AW, Sheldon TA. Compression for venous leg ulcers (Cochrane Review). *Cochrane Database Syst Rev*. 2004; 3.
19. Layton AM, Ibbotson SH, Davies JA, Goodfield MJD. Randomised trial of oral aspirin for chronic venous leg ulcers. *Lancet* 1994;344:164-5.
20. Longiave, D, Omini, C, Nicosia, S, Berti, F. The mode of action of aescin on isolated veins: Relationship with PGF2 alpha. *Pharmacol Res Commun* 1978;10:145.
21. Falanga V, Fujitani RM, Diaz C, et al. Systemic treatment of venous leg ulcers with high doses of pentoxifylline; efficacy in a randomized, placebo-controlled trial. *Wound Repair Regen* 1999;7:208-13.
22. Kjaer ML, Jorgensen B, Karlsmark T, Holstein P, Simonsen L, Gottrup F. Does the pattern of venous insufficiency influence healing of venous leg ulcers after skin transplantation? *Eur J Vasc Endovasc Surg* 2003;25:562-7.
23. Falanga V, Margolis D, Alvarez O, et al. Rapid healing of venous ulcers and lack of clinical rejection with an allogenic human skin equivalent. *Arch Dermatol* 1998;134:293-300.
24. Falanga V, Sabolinski M. A bilayered living skin construct (Apligraf) accelerates complete closure of hard to heal venous ulcers. *Wound Rep Reg* 1999;7:201-7.
25. Jones JE, Nelson EA. Skin Grafting for venous leg ulcers (Cochrane Review). *Cochrane Database Syst* 2006;3.
26. Thomas S. Compression Bandages. In: Cullum N, Roe BH, editors. *Leg Ulcers: nursing management*. Harrow: Scutari, 1995.